An Ongoing Series

Mobility Solutions After a Lower Extremity Fracture and Applicability to Battlefield and Wilderness Medicine

Lee W. Childers, PhD[1]; Joseph F. Alderete, MD[2]; Travis D. Eliason, BS[3]; Stephen M. Goldman, PhD[4]; Daniel P. Nicolella, PhD[5]; Sarah N. Pierrie, MD[6]; Gerald E. Stark, PhD[7]; Nicholas M. Studer, MD, NRP[8]; Joseph C. Wenke, PhD[9]; Jonathan B. Wilson, DPT[10]; Christopher L. Dearth, PhD[11]*

ABSTRACT

The potential for delayed evacuation of injured Servicemembers from austere environments highlights the need to develop solutions that can stabilize a wound and enable mobility during these prolonged casualty care (PCC) scenarios. Lower extremity fractures have traditionally been treated by immobilization (splinting) followed by air evacuation – a paradigm not practical in PCC scenarios. In the civilian sector, treatment of extremity injuries sustained during remote recreational activities have similar challenges, particularly when adverse weather or terrain precludes early ground or air rescue. This review examines currently available fracture treatment solutions to include splinting, orthotic devices, and biological interventions and evaluates their feasibility: 1) for prolonged use in austere environments and 2) to enable patient mobilization. This review returned three common types of splints to include: a simple box splint, pneumatic splints, and traction splints. None of these splinting techniques allowed for ambulation. However, fixed facility-based orthotic interventions that include weight-bearing features may be combined with common splinting techniques to improve mobility. Biologically-focused technologies to stabilize a long bone fracture are still in their infancy. Integrating design features across these technologies could generate advanced treatments which would enable mobility, thus maximizing survivability until patient evacuation is feasible.

KEYWORDS: *Prolonged casualty care; combat fractures; lower extremity; mobility; splinting; wilderness*

Introduction

Recent advances in body armor, combat casualty care (including prehospital care), and air transport have improved warfighter survivability in recent conflicts. In the Global War on Terror, and later the Central Command Overseas Contingency Operations, an estimated three quarters of survivable injuries in American and British troops involved the extremities.[1–4] Among patients with fractures, up to 60% involved the lower extremities, in part due to the high proportion of injuries caused by buried or surface-level improvised explosives.[2] Analysis of recent conflicts fought in austere environments such as Latin America and the Sahel identified similar injury patterns.[5,6] As such, these combat-related extremity injuries have constituted a high proportion of theater evacuations in recent conflicts.[4]

*Correspondence to walter.l.childers.civ@health.mil

[1]**Dr Lee W. Childers** is affiliated with DoD/VA Extremity Trauma and Amputation Center of Excellence and the Center for the Intrepid, Department of Rehabilitation Medicine, Brooke Army Medical Center, both at JBSA Ft. Sam Houston, TX, and the Department of Rehabilitation Medicine, Uniformed Services University of the Health Sciences, Bethesda, MD. [2]**Dr Joseph F. Alderete** is a physician affiliated with the Center for the Intrepid, Department of Rehabilitation Medicine, Brooke Army Medical Center, JBSA Ft. Sam Houston, TX, and the U.S. Army Institute of Surgical Research, Brooke Army Medical Center, JBSA Ft. Sam Houston, TX. [5]**Dr Daniel P. Nicolella** and [3]**Travis D. Eliason** are affiliated with the Musculoskeletal Biomechanics Section, Materials Engineering Department, Southwest Research Institute, San Antonio, TX. [4]**Dr Stephen M. Goldman** is affiliated with DoD/VA Extremity Trauma and Amputation Center of Excellence, JBSA Ft. Sam Houston, TX, and the Department of Surgery, Uniformed Services University of the Health Sciences – Walter Reed National Military Medical Center, Bethesda, MD. [6]**Dr Sarah N. Pierrie** is a physician affiliated with the Center for the Intrepid, Department of Rehabilitation Medicine, Brooke Army Medical Center, JBSA Ft. Sam Houston, TX, and the Department of Orthopedics and Rehabilitation, Brooke Army Medical Center, JBSA Ft. Sam Houston, TX. [7]**Dr Gerald E. Stark** is affiliated with 8Professional Clinical Services, Ottobock Healthcare, Austin, TX, the Department of Engineering Management and Technology, University of Tennessee at Chattanooga, Chattanooga, TN, and Northwestern University Prosthetics and Orthotics Center, Northwestern University, Chicago, IL.[8]**Dr Nicholas M. Studer** is a physician affiliated with the U.S. Army Institute of Surgical Research, Brooke Army Medical Center, JBSA Ft. Sam Houston, TX. [9]**Dr Joseph C. Wenke** is affiliated with the U.S. Army Institute of Surgical Research, Brooke Army Medical Center, JBSA Ft. Sam Houston, TX and the Shriners Children's Texas, Galveston, TX. [10]**Mr. Jonathan B. Wilson** is affiliated with the Center for the Intrepid, Department of Rehabilitation Medicine, Brooke Army Medical Center, JBSA Ft. Sam Houston, TX, the Department of Rehabilitation Medicine, Uniformed Services University of the Health Sciences, Bethesda, MD, the Henry M. Jackson Foundation for the Advancement of Military Medicine, Bethesda, MD, and Alabama College of Osteopathic Medicine, Dothan, AL. [11]**Dr Christopher L. Dearth** is affiliated with the DoD/VA Extremity Trauma and Amputation Center of Excellence, JBSA Ft. Sam Houston, TX and the Department of Surgery, Uniformed Services University of the Health Sciences – Walter Reed National Military Medical Center, Bethesda, MD.

However, future conflicts with a peer and/or near-peer adversary are likely to create situations in which far-forward combat units operating in austere environments will be denied ground and air operational support.[7] The subsequent lack of air superiority may delay casualty evacuation for days or even weeks, far exceeding the traditional "Golden Hour."[8] This may be associated with additional challenges, such as the need for ground unit mobility to evade an adversary's attack.[9] This evolving paradigm highlights the ever-growing importance of prolonged casualty care (PCC), defined as the provision of care in austere environments when evacuation to a more traditional fixed-based hospital is unavailable.[8,10]

Challenges to providing prolonged casualty care (PCC) in far-forward or remote environments include limited space for supplies among dismounted medical teams; fighting and approach loads for a Combat Medic are 24.7-kg (54.5-lb) and 41.6-kg (91.7-lb) respectfully, which would limit their ability to carry more items.[12] Further challenges would be presented by lack of far-forward surgical support, risk to rescuers in difficult terrain, and the need for dedicated air support.[5,11] Nearly 25% of recent PCC scenarios were under enemy fire, thus additionally complicating the provision of medical care.[13]

Many characteristics of PCC are also seen in the civilian sector, in which managing lower extremity injuries sustained in wilderness areas involves overcoming many of the same challenges as battlefield injuries sustained in austere environments. Up to three-quarters of injuries to individuals participating in mountaineering, rock climbing, canyoning, and caving involve the lower extremities, with 41% of injuries resulting in fractures.[14–17] While the most common mechanism of injury for civilians engaged in recreational wilderness activities is a fall (as opposed to a blast injury), the environment and severity of those injuries make many aspects of wilderness patient care similar to those faced by providers in far-forward military operations. For example, challenges include the following: the remote locale, limited communication between the point of injury and higher levels of care, limited or delayed rescue capabilities (via air or ground resources), lack of point-of-care medical resources, and physical risk to rescuers.[18] Harsh or volatile weather conditions may compound these difficulties.

Several splinting designs have been developed as commercial products or improvised in the field, yet it is unclear if these could be used to enable mobility until more definitive treatment is available. Likewise, there are orthotic designs that enable weight-bearing mobility, but these may not be available in PCC scenarios. Finally, several novel and biologically-focused technologies have been proposed that may stabilize the individual and allow them to bear weight on a fractured bone. Lessons learned from these treatment developments may facilitate repurposing available technology or generating new technology for PCC scenarios. The development of solutions that mitigate the effects of lower extremity injuries in PCC scenarios will have a major impact on both military and civilian personnel.

The goal of this literature review was to define the challenges associated with managing extremity injuries in a PCC scenario. Then, the objectives were to identify technologies that could be used temporarily to stabilize lower extremity fractures and even enable early mobility until the patient can be evacuated to more resourced echelons of care (e.g., forward surgical teams, a hospital, etc.). Finally, the authors aimed to evaluate the feasibility of employing these devices and techniques in austere environments and recommend design improvements that may advance patient care.

Methods

The literature search was executed using scientific search engines (e.g., PubMed, Web of Science, Google Scholar, etc.). The literature review was divided into key topic areas: 1) commercially available splints, 2) improvised splinting techniques, 3) orthotic interventions, and 4) biomaterial approaches to local fracture stabilization. Abstracts and conference proceedings written in English were included, and there were no exclusions based on publication year. The bibliographies of articles identified by the initial search were examined to find previously published literature. In an effort to gain access to articles describing the most modern techniques, forward searches were executed to locate papers referencing key literature identified previously as using the aforementioned approaches.

Fracture Management in the Austere Environment

Splinting, or the provisional immobilization of an injured extremity, is the current standard of care for orthopedic injuries sustained in the field in order to facilitate casualty transportation by MEDEVAC or CASEVAC (Figure 1). The benefits of fracture immobilization through splinting include pain management, protection of injured soft tissues, and, depending on the technique, application of traction or provisional reduction. It also contributes to reduced blood loss, compression on adjacent neurovascular structures, and risk of fat embolism and pulmonary complications.[19–25] Splinting is appropriate for early post-injury care or when more definitive treatment options such as surgical management are not immediately available (e.g., PCC scenario) or appropriate (e.g., sub-sterile conditions).

Splints employed in the austere prehospital environment should be lightweight and easily packaged but strong enough to immobilize a fractured limb, especially if it needs reduction. They must also be adaptable across a range of limb shapes and sizes. Excellent designs allow for wound access and can be quickly applied with minimal personnel with limited medical training.[23,26] Designs that apply constant circumferential pressure should be avoided for lower extremity injuries if the person develops an acute compartment syndrome.[27] Splints can be made from fiberglass or plaster, pre-packaged (i.e., commercially available), or can be improvised in the field using principles outlined in this review and with available materials (Table 1). In addition to satisfying these basic requirements, the ideal device would allow early patient mobilization (current splints do not allow for weight bearing), which would thereby facilitate team/unit mobility during PCC scenarios. The following sections will explore prefabricated and improvised splint designs.

The common characteristics described above led to the development of several splint designs. Simple preformed wooden splints were used successfully during the U.S. Civil War, while the Thomas traction splint, developed in the late 1800s, was utilized in the prehospital setting from World War I through modern conflicts (Figure 2).[23,28–31] The Thomas splint's bi-polar design provides traction, stability, and as a consequence, hemorrhage control for complex femur injuries (Figure 3).[28–30] By

FIGURE 1. ***Common splints.*** *Three common prehospital splinting techniques include:* **(A)** *a traction splint that pulls the fractured limb distally;* **(B)** *a simple "box splint," that stabilizes the fracture with a rigid support around three sides; and* **(C)** *a vacuum splint that encloses and molds thousands of small balls around an injured extremity and can provide rigid support after deflation.*

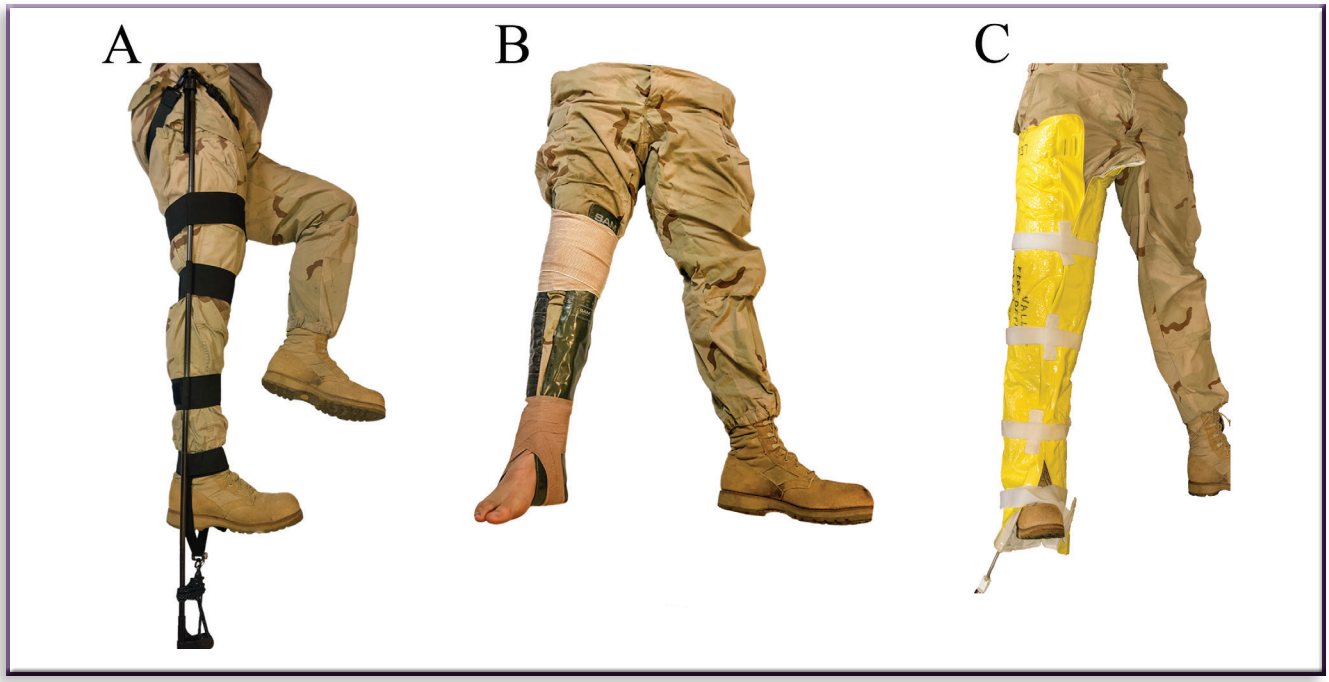

TABLE 1 *Splint Advantages and Disadvantages – Different Types of Splints That Could Be Used in a Far-Forward Environment and their Associated Advantages and Disadvantages*

Intervention	Advantages	Disadvantages
Plaster or Fiberglass Bandage	Malleable, lightweight, compact, may allow weight bearing	Long hardening times (1/2 - 72 hours), limited wound access, sensitive to environmental factors (e.g., precipitation)
SAM® Splint	Adaptable, lightweight, portable, allows wound access, short application time (203 seconds)	Difficult to maintain fracture alignment and traction, allows motion between the limb and device
Spray Foam Cast	Adaptable, lightweight, portable, simple and rapid application (68 seconds), rapid set time (60 seconds), robust	Limited wound access
Traction Splint	Adaptable, compact, allows wound access, maintains traction, relatively short application time (≤5 minutes), one person application	Does not allow weight bearing
Air Splint	Lightweight, customizable pressure to tissues, rapid application	Limited durability and adaptability, limited ability to provide traction
Vacuum Splint	Adaptable, customizable pressure to tissues, one person application	Limited wound access, does not allow for weight bearing, requires a vacuum apparatus, limited durability, prone to environmental factors
Improvised Splint	Adaptable, uses readily available materials, may allow wound access, one person application, can add supplemental traction	Difficult to maintain fracture alignment, allows for motion between limb and apparatus, does not allow weight bearing

placing a shoe lift on the contralateral side, the Thomas splint has even permitted ambulation post-injury.[28,31] A primary drawback to the Thomas splint design is its lack of portability, which led to the development of collapsible splinting systems, such as the CT-6 traction splint (Faretec Inc., https://www.faretec.com/) and lightweight designs, such as the simple structural aluminum malleable SAM® splint (SAM Medical, Tualatin, OR, https://www.sammedical.com/) (Figures 1A, 1B).

The Thomas splint led the way for the modern prefabricated traction splint. Traction splints require one or two rigid poles running along the long axis of the extremity and a mechanism to pull the extremity distally to minimize motion between bone fragments (Figures 1A, 3). A splint that provides traction of at least 10% of the patient's body weight may help reduce pain, protect neurological and vascular tissues, and reduce fracture-related internal hemorrhage in individuals with lower extremity long bone fractures.[20,21,23,32] This class of splint is most commonly used to treat femur fractures and fractures around the knee. Despite their relatively simple design, several pitfalls have been identified. First, the length of components required to span the entire lower limb makes traction splints relatively cumbersome and requires some assembly. Second, the ability of various designs to maintain traction over time has been brought into question. In one study, simple frame-based splints applied by civilian medical personnel were not able to maintain the optimal traction of 10% bodyweight, as measured 30 minutes after application.[32] However, other studies showed successful application of the same type of splint immediately after application to a mannequin that does not

FIGURE 2. ***Civil War splints*** *– Examples from the U.S. Civil War of simple prefabricated splints made from hand-formed wooded sections that would be strapped to the injured lower extremity.*

FIGURE 3. ***The Thomas Splint*** *– The Thomas Splint consists of a semicircular padded bar designed to sit on the ischial tuberosity (bony prominence on the posterior of the pelvis) with a belt that secures it to the proximal thigh. Two rigid bars protrude distally to stabilize the limb and allow traction to be applied off the distal aspect of the splint. This example is from World War I and does not show the straps used to stabilize the limb and pull the limb distally to provide traction.*

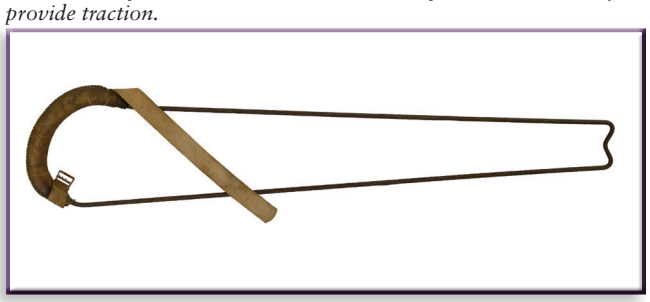

have active muscle control, meaning the differences could be from a live human shifting around.[23] Differences in producing successful traction may be due to the training and experience of the personnel applying the devices or to differences in design and application techniques.

In instances in which traction is contraindicated, such as crush injuries that may result in compartment syndrome, field medical personnel may employ a simple "box splint" design.[27] Historically, this was performed by strapping an injured extremity to a piece of wood (Figure 2). More recently, the SAM splint, developed during the Vietnam War, consists of a sheet of padded aluminum that can be hand-formed around the injured anatomy (Figure 1B). Air splints employ air-filled bladders for customizable levels of pressure and thus fracture stabilization at the injury site.[33] Vacuum splints involve a vinyl envelope filled with small individually-compressible balls of material (e.g., polystyrene) that stabilize a fracture and may provide structural stability via "granular jamming" (compression of granular materials within the apparatus when negative pressure is applied) (Figure 1C).[34–36] Vacuum splints are light and compact; single splint options weigh between 0.2 to 1.0-kg, while a case of three splints and a portable vacuum pump weighs 2.9-kg (EVAC-U-SPLINT®, Hartwell Medical, Carlsbad CA, https://www.hartwellmedical.com/evac-u-splint-extremity-splints/).

In-field application time is another important performance metric and varies significantly between splint designs. For example, an innovative spray-on foam splint provides the fastest application time, taking just 68 seconds to apply to a simulated tibia fracture and an additional 60 seconds to cure.[26] In contrast, the SAM splint requires an average of 203 seconds to stabilize a simulated tibia fracture.[26] Similar application times were reported for the fiberglass wrap, FastSet3 (FareTec Inc., Painesville OH, https://www.faretec.com/), which reaches rigidity approximately 3 minutes after being activated by water and applied to the affected limb. Frame-based traction splints take upwards of 350 seconds to apply correctly to a more complicated simulated injury, such as a femur fracture.[23] Plaster splints take the longest to apply, as the materials often take up to 30 minutes to set properly.[37] Application time for prefabricated air bladder-based splints is suspected to be low based on their simple design but has not yet been published.[36] Importantly, analyses of splint applications do not routinely include other aspects of splint placement, such as positioning for application and unpacking. In total, splinting adds an estimated 1.8 to 9 minutes to the prehospital scene time if statistics from civilian settings are extrapolated to other contexts.[38,39] However, the additional time to apply a splint on the battlefield or in an austere environment may vary even more, depending on the terrain, tactical situation, weather, and personnel available to assist. Thus, splint application time must be balanced with considerations such as field expediency and the ability to improve casualty or unit mobility. Future research should quantify the total time to apply and use a splint system, not just application time, to give rescuers a better estimate of time factors associated with splint utilization.

The ease of which medical personnel can confidently use and apply a splint may influence its battlefield or remote application success. Intuitively, designs that model simplicity by way of fewer parts and an obvious application procedure should perform favorably. In general, traction splint designs with one rigid component (unipolar) outperform their bipolar counterparts in subjective ratings of application confidence, pre-application handling, and appropriateness for battlefield use.[23] Nevertheless, several designs have issues that limit their utility or safety. For example, the SAM splint consistently demonstrated poor performance across metrics related to its successful application despite its simple design. User concerns related to the SAM splint included poor protection of neurovascular structures, difficulty achieving and maintaining traction, and excessive relative motion at the fracture site when compared to other designs.[26] These issues demonstrate that even simple designs such as the SAM splint require basic knowledge of human anatomy, structural design, and fabrication skills to achieve an appropriately contoured safe application. In contrast, the spray-foam splint received high subjective ratings on reproducibility and ability for an untrained individual to apply when compared to the SAM splint.[26]

There are several limitations common to prefabricated splints currently available for use in PCC and wilderness rescue scenarios. For example, in-field splinting has not enabled weight-bearing or mobility post-application. Although air splints have been designed to allow weight bearing after transtibial amputation,

these semi-custom units would have limited availability and durability in an austere environment.[40] Future work on prefabricated splints for in-field fractures could leverage some design features from femur fracture (usually traction-type) splints to enhance mobility. For example, transferring loads around the fracture site to the pelvis (usually to the ischium) while providing longitudinal structural rigidity to the limb may enable weight-bearing through the device and promote ambulation. Other limitations of prefabricated splints include long application times as well as potential loss of traction over time.[39] Novel designs that address these pitfalls will likely be more complicated than what has been traditionally used for in-field fracture care. Thus, innovators should make every effort possible to specifically define the goals and requirements of each new design to produce the most effective product possible.

Improvised Splinting Techniques

Improvised splinting techniques offer advantages for austere environments and during PCC scenarios when commercial immobilization options may not be available (Figure 4). Bracing an extremity in these resource-constrained environments may require the use of materials found in Soldiers' or hikers' packs or in the local environment.[41] For example, the improvisation of a splint using the Soldier's rifle was used until the issue of shorter rifles (~1911), after which the 'rifle splint' was replaced with wooden sticks and utilized other materials available to the medical provider.[41,42] During World War I, these improvised splinting systems were superseded by the Thomas splint once its availability improved.[43,44] In addition, closed-cell foam pads, common in backcountry scenarios, can be employed to provide structural integrity around a fractured limb, while traction can be applied by creating an ankle hitch that utilizes fabric (e.g., webbing) to circumvent the ankle joint and pull the extremity distally (Figure 4).[20,22,45] To augment stability and further minimize interfragmentary motion, rigid supply items such as ski poles, tent poles, or pieces of wood can be placed along the long axis of the limb, either unilaterally or bilaterally.[22] When secured to the traction apparatus surrounding the individual's ankle, these supports may provide self-contained traction to the affected limb. Such improvised traction splinting techniques have been shown to be equally effective as commercially available devices.[32] Improvised traction splinting may also incorporate the litter to provide the rigid structure for traction application or be made from a crutch, albeit neither of these options would enable independent mobility.[46,47] The potential need for PCC by both military and civilian personnel highlights the importance of examining alternative options to prefabricated braces and techniques.

Traction may be contraindicated in circumstances that sometimes occur alongside fractures, such as compartment syndrome.[27] In these scenarios, a simple improvised splint (e.g., box splint) can be applied to immobilize the fracture. Improvised splints, particularly when applied to fractures below the knee, should immobilize the joint above and below the fracture (usually the knee and the ankle) non-circumferentially to allow for swelling.[20,22,45,48] These splints can be made from the same structural resources as previously described for traction splints (e.g., closed-cell foam pads and ski poles), yet without the capability of pulling the limb distally. In an austere environment, other materials can be used as substitutes for items, such as the large closed-cell foam pads common to wilderness packs. For example, personnel in combat units routinely have access to hydration bladders capable of holding 70-oz of water that, when filled, can be used to stabilize an extremity fracture.[49] A civilian case report documented the successful use of an inflated hydration bladder in conjunction with a rigid item from the environment (e.g., a stick) to supply additional structural support along the long bones of the forearm, a design reminiscent of commercial air splints.[50] Not only does this improvised hydration bladder splint immobilize the fracture site, the inflated bladder may apply modifiable pressure that can optimize hemorrhage control.[50] In fact, the International Commission for Mountain Emergency Medicine recommends the use of a compression splint/pressure dressing for traumatic injuries that involve hemodynamic instability.[51] Multiple inflated

FIGURE 4. ***Improvised splint*** *– This improvised traction splint is made up of a closed-cell foam trail chair, knife sheath, tent poles as rigid support, a hydration pack for proximal padding and support, and straps from a pack to secure the improvised splint to the affected limb.*

hydration bladders could potentially be combined to grossly and hemodynamically stabilize larger extremity injuries.

Improvisation using vacuum splint techniques is limited due to the nature of available materials and the need for a vacuum apparatus. However, Air Force Pararescuemen carry a V-Vac suction system in their primary medical kit.[45] This apparatus may be utilized with available materials, such as a waterproof bag, standard to many field medical personnel, filled with soft materials (e.g., clothing/gauze). This mirrors the granular jamming demonstrated in conventional vacuum splints. These examples underscore the potential for creating innovative improvised splinting techniques using materials available to combat or wilderness units in PCC scenarios and the extant need to evaluate the effectiveness of these designs.

Orthotic Interventions

Functional fracture orthoses for definitive fracture management also highlight design features that could be used in splints developed for PCC scenarios (Figure 5). Functional fracture orthoses accomplish stabilization by employing the principle of radial soft tissue compression around a long bone fracture. Further, these orthotic interventions incorporate anatomic and mechanical support structures to off-load from the fracture site, enabling weight bearing and encouraging mobility. Functional fracture orthoses have demonstrated success in traditional, definitive orthotic care scenarios due to the ability to adjust to volumetric fluctuations. This has resulted in faster healing rates and decreased monetary expense compared to plaster casting, while being less medically invasive than surgical fixation.[52–55] Notably, fracture orthoses are not designed to eliminate interfragmentary motion because successful fracture healing is dependent upon achieving a specific mechanical environment, wherein an optimal amount of interfragmentary motion is allowed at the fracture site and controlled by the stiffness of a stabilization device.[56,57] Proper control of interfragmentary motion allows for the sustained vascularization in the fracture callous that is required for successful ossification.[58] Fracture callous formation, critical to this fracture care technique, is achieved via flexible fracture fixation or stabilization that allows for 0.2–1.0-mm interfragmentary motion at a fracture site displaced by 2-mm.[57] In contrast to small axial deformations, shear displacement at the fracture site has been shown to significantly delay facture healing, possibly leading to fracture non-union.[59,60] The use of fracture orthoses have been primarily indicated in the management of low-energy closed fractures of the tibia with >12-mm shortening and >5° angulation after reduction.[55] Tibial fracture orthosis contraindications include presence of an intact fibula, polytrauma cases that prevent ambulation, or axially unstable fractures.[53,55] While most battlefield injuries to the extremities involve polytrauma, in which a traditional fracture orthosis will be contraindicated, there are multiple design features in fracture orthoses that have applicability for enhanced mobility in PCC scenarios. If fracture care treatments within PCC scenarios can also incorporate the optimal ranges of interfragmentary motion, then these PCC treatments may be complementary to definitive fracture treatment rendered after evacuation to higher echelons of care.

The evolution of current functional fracture orthoses was developed out of a blending of prosthetic and orthotic design principles in the mid-1900s (Figure 5). These designs started as traditional leather-upper offloading devices called "axial resist orthoses," functioning to unweight the ankle and calcaneus via a rigid frame that bypasses the foot and ankle and connects to the shoe.[61,65] Device design was improved by replacing the leather component with more rigid thermoplastic components, resulting in several commercially available devices (Figure 5A).[52,53,55,61,66–72] These devices have an adjustable interface to simultaneously compensate for volumetric changes caused by swelling while applying compression to soft tissues and circumventing the long bone fracture. Compression to the soft tissues derives from principles associated with a patellar tendon-bearing prosthesis (PTB). The PTB was designed to apply loads through tissues in a transtibial residual limb that can tolerate loading (e.g., the tibialis anterior interosseous area between the tibia and fibula), while off-loading tissues that are sensitive to pressure (e.g., crest of the tibia, proximal head of the fibula). Current functional fracture orthotic interventions reportedly increase patient satisfaction and reduce pain during ambulation (Figure 5B).[61–64,73,74] Further, many of these design features have been incorporated into more modern treatments, such as the Intrepid Dynamic Exoskeleton Orthosis, for individuals that have undergone complex limb salvage operations and wish to return to high-level activities, including return to duty (Figure 5C).[75,76]

The use of a functional femur fracture orthosis for compression-based stabilization and off-loading of femur fractures presents challenges due to larger amounts of soft tissue surrounding the femur compared to that around the tibia. Yet, designs developed for femoral fractures nevertheless rely on prosthetic off-loading design principles. By relying on the ischial tuberosity of the pelvis in conjunction with a rigid structure running parallel to the intact leg and down to the ground, ambulation has been achieved. The ischial tuberosity has been used in both the Quadrilateral socket design from the 1950s and the modern ischial containment socket prosthetic designs, intended for individuals with transfemoral amputation.[77,78] Incorporating a proximal shelf that contacts the ischial tuberosity of the pelvis reportedly off-loads the femoral shaft by 65% and reduces loads on the femoral neck by 30% during walking, thus demonstrating the potential to utilize pelvic structures to off-load lower limb fractures in devices employed in austere environments.[79]

Fracture orthoses have several design features that are applicable to the development of devices capable of being employed in a PCC scenario, particularly in the absence of surgical stabilization. The use of circumferential pressure applied along the limb segment through an adjustable interface may be sufficient to limit interfragmentary motion while allowing volumetric changes and access to wounded tissues. Utilizing the proximal tissues and a frame to bypass and off-load the injured tissues may provide opportunities for mobility after injury. The incorporation of energy storage and return components based on design features in the Intrepid Dynamic Exoskeleton. Orthosis may also enhance this mobility.

Biomaterial Approaches to Local Fracture Stabilization

While providing external mechanical stabilization to fractures, thereby enabling the injured person to bear weight, would be a significant advancement in managing extremity injuries within an austere environment, an opportunity also exists to

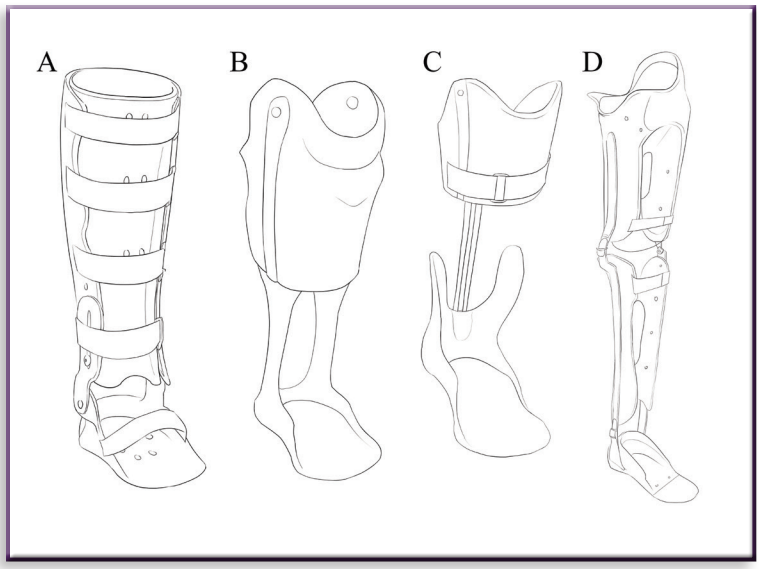

FIGURE 5. ***Off-loading orthoses –*** *Examples of different orthotic interventions that unweight limb segments:* **(A)** *the thermoplastic fracture orthosis stabilizes a closed tibia fracture through circumferential pressure around the shank while unweighting the limb via the articulated foot section;* **(B)** *the patellar tendon bearing or axial resist ankle–foot orthosis is designed to unweight (but not stabilize) the fracture site transferring the load to unimpaired tissues in the proximal shank;* **(C)** *the Intrepid Dynamic Exoskeletal Orthosis enables running while off-loading the distal shank;* **(D)** *an Ischial Weight Bearing Knee–Ankle–Foot Orthosis has a shelf on the proximal thigh section that allows for weight transfer through the device and around the entire limb to the ischial tuberosity of the pelvis. Primary disadvantages to their use in austere environments involve limited portability due to being custom made in fixed and specialized facilities.*

temporarily stabilize the fracture site locally in an internal fashion with respect to the mechanical and/or biological microenvironment. This concept, however, is fraught with challenges related to the environment being resource poor (e.g., lack of sterile surgical fields), and the nature of the tactical combat and wilderness injuries (e.g., open fractures), which are characterized by concomitant soft tissue injuries and high levels of contamination.[4] As such, existing clinical practice guidelines for management of these wounds would advise against primary closure and/or placement of foreign bodies, such as internal fixation devices, as each would increase the likelihood of infection.[80] Thus, to achieve success in utilizing a biomaterial approach for fracture stabilization within a PCC environment, design criteria need to exhibit characteristics traditionally thought to be inversely related to each other. For example, the materiel solution would need to be sufficiently porous and/or degradable to allow for the ability to deliver clinically relevant antibiotic payloads, while also supplying sufficient mechanical stability to support weight bearing. As such, this is a challenging area, and our thorough literature review did not identify any currently available materiel solution that could meet all the necessary requirements.

The Defense Advanced Research Projects Agency (DARPA), however, did solicit proposals in 2008 to develop a "fracture putty" to facilitate healing of segmental fractures. While the DARPA funding call did not explicitly require the consideration of a PCC operational environment in its design criteria, it was envisioned that such materials would preferentially bind to bone and allow full weight bearing within seven days. Moreover, it was envisioned that the resultant materiel product would be fully degradable, non-toxic, non-antigenic, and serve to deliver bioactive payloads (e.g., osteo-inductive agents and/or antibiotics) where appropriate, to create an optimal mechanical environment for bone ingrowth. In addition, the materiel product would also theoretically be low pack volume and easy to use. While these efforts have not yet delivered a fielded materiel solution, the concepts laid out by DARPA may represent an ideal starting point for PCC-focused interventions.

Alternatively, if the load bearing requirement of a putative fracture putty was removed (e.g., due to the combinatorial utilization of an exoskeleton-like device to facilitate mechanical off-loading), it would greatly expand the technical options currently available to develop a soft polymeric material, such as highly tunable synthetic and/or biologic hydrogels. Hydrogels are routinely used within the field of regenerative medicine to mediate the local delivery of bioactive payloads at clinically relevant concentrations over a prolonged period of time relative to systemic delivery. As such, they represent a unique platform technology to facilitate the spatiotemporally controlled release of antibiotics and/or growth factors needed to control infection, accelerate healing, and/or dampen pathologic wound repair processes. To that end, one promising report by Johnson et al. describes an injectable polyethylene-glycol-based hydrogel that adheres to fracture surfaces and delivers an antimicrobial enzyme over the course of 24 hours to control infection and support fracture repair.[81] While this study likely does not represent a permanent solution for PCC fracture care, it does represent the type of approach that could be a viable solution. In other words, it embodies the idea that early treatment of the unique sequela of battlefield fractures is paramount for optimization of subsequent fracture healing outcomes, and represents another starting point for iterative improvements (e.g., targeting of endogenous stem cell populations). Continued investment toward the development of an optimized biomaterial approach for local fracture stabilization within an austere environment is therefore warranted. Biomaterial advances in conjunction with an exoskeleton will likely facilitate temporary, in field, return to duty of injured Servicemembers when evacuation to higher echelons of care is delayed.

Conclusion

The likelihood that U.S. Forces will not have air superiority in future conflict highlights a need for developing novel/next generation materiel solutions that allow for mobility after incurring a lower extremity fracture during a PCC scenario. Austere environments, and the consequent delayed evacuation times, prevent the ability to surgically stabilize these fractures. Literature continues to support the use of splinting after a fracture as a prehospital intervention to reduce pain, protect soft tissue structures of the injured limb, and provide traction (when traction is indicated).

Field expedient care that may enable mobility currently relies on improvising solutions using materials available to the rescuer and leveraging principles from prosthetic/orthotic designs. In short, location of long and rigid items (e.g., branches, tent poles, ski poles, etc.) that can transfer energy from the ground, around the splinted fracture site, and to proximal anatomy that can support weight (e.g., anterior proximal tibia, ischial tuberosity of the pelvis, etc.) can be used to improvise mobility solutions in austere environments without placing additional weight burden on the medical provider. There is little literature on best improvisation practice for such devices in the field or how well they may stabilize a fracture and enable mobility. Therefore, caution should be used when implementing these field-based treatments, while also recognizing and balancing the priorities of threats to life vs. threats to limb when hospital care will be delayed. To maximize the feasibility of such devices, consideration should be given to incorporation of biomaterial interventions that may both internally stabilize a fracture and allow for antibacterial materials to be delivered to the injury site. While the development of these biomaterial interventions I still in its infancy, continued developments in and integration with exoskeletal technologies, both improvised and commercially available, will help address known capability gaps for operational readiness in PCC scenarios.

Acknowledgements

The authors gratefully acknowledge COL Johnny Paul and MAJ Robert Blume of the U.S. Army Combat Medic Support Training Program, Chief Shane Reddout of Bexar County Emergency Services District No. 8, Ft. Sam Houston, Tx, and the staff of the U.S. Army Medical Department Museum, Ft. Sam Houston, Tx for providing examples of historical and modern splints for us to photograph; Erica Vasquez of Brooke Army Medical Center, Ft. Sam Houston, Tx for illustrating the fracture orthoses; and Noel Guerrero and Tyler Cagle in the Military Performance Laboratory at the Center for the Intrepid, Brooke Army Medical Center for preparing the figures for print.

Funding

This work was partially supported with internal funds from the Department of Defense (DoD/Veterans Administration (VA) Extremity Trauma and Amputation Center of Excellence and partially supported by research grant W81XWH-21-2-0004 from the DoD Clinical and Rehabilitative Medicine Research Program.

Author Contributions

WLC, JFA, TDE, SMG, DPN, SNP, and GES participated in study design. WLC, TDE, SMG, DPN, SNP, GES, and JBW participated in literature acquisition. All authors participated in analysis of literature, manuscript drafting, and critical revision of this manuscript. All authors approved the final version of this manuscript.

Conflicts of Interest

The authors have no conflicts of interest to disclose.

Disclaimer

This material is declared a work of the U.S. Government and is not subject to copyright protection in the United States. Approved for public release; distribution is unlimited. The view(s) expressed herein are those of the author(s) and do not reflect the official policy or position of Brooke Army Medical Center, Ft. Sam Houston, Tx, the U.S. Army Medical Department, the U.S. Army Office of the Surgeon General, the Department of the Air Force, the Department of the Army, the DoD, or the U.S. Government.

References

1. **Belmont PJ, Schoenfeld AJ, Goodman G.** Epidemiology of combat wounds in Operation Iraqi Freedom and Operation Enduring Freedom: orthopaedic burden of disease. *J Surg Orthop Advn*. 2010;19(1):2–7.
2. **Chandler H, MacLeod K, Penn-Barwell JG, et al.** Extremity injuries sustained by the UK military in the Iraq and Afghanistan conflicts: 2003–2014. *Injury*. 2017;48(7):1439–1443.
3. **Dougherty AL, Mohrle CR, Galarneau MR, et al.** Battlefield extremity injuries in Operation Iraqi Freedom. *Injury*. 2009;40(7):772–777.
4. **Owens BD, Kragh JF, Jr., Macaitis J, et al.** Characterization of extremity wounds in Operation Iraqi Freedom and Operation Enduring Freedom. *J Orthop Trauma*. 2007;21(4):254–257.
5. **Travers S, Carfantan C, Luft A, et al.** Five years of prolonged field care: prehospital challenges during recent French military operations. *Transfusion*. 2019;59(S2):1459–1466.
6. **Akpoto YM, Abalo A, Adam S, et al.** Extremity injuries in soldiers during the conflict in Mali: Experience of Togo Level two Hospital. *Int Orthop*. 2015;39(10):1895–1899.
7. **Army U.S. TRADOC Pamphlet 525-3-1.** *The U.S. Army in Multi-Domain Operations 2028*. 6 December 2018. https://adminpubs.tradoc.army.mil/pamphlets/TP525-3-1.pdf. Accessed 18 September 2023.
8. **Keenan S, Riesberg JC.** Prolonged field care: beyond the "golden hour". *Wild Environ Med*. 2017;28(2):S135–S139.
9. **Karlberg EJ, Cook CBC.** *Strategic training management: Training to win in a complex world*. U.S. Army War College; 2016. https://publications.armywarcollege.edu/publication/strategic-training-management-training-to-win-in-a-complex-world/. Accessed 18 September 2023.
10. **Keenan S**. Deconstructing the definition of Prolonged Field Care. *J Spec Oper Med*. 2015;15(4):125.
11. **Mucciarone JJ, Llewellyn CH, Wightman JM.** Tactical combat casualty care in the assault on Punta Paitilla Airfield. *Mil Med*. 2006;171(8):687–690.
12. **Dean C.** The modern warrior's combat load. Dismounted operations in Afghanistan, April-May 2003. 2004. https://alamancerangers.files.wordpress.com/2012/01/modernwarriorscombatloadreport.pdf. Accessed 18 September 2023.
13. **DeSoucy E, Shackelford S, DuBose JJ, et al.** Review of 54 Cases of Prolonged Field Care. *J Spec Oper Med*.17(1):121–129.
14. **Soteras I, Subirats E, Strapazzon G.** Epidemiological and medical aspects of canyoning rescue operations. *Injury*. 2015;46(4):585–589.
15. **Stella-Watts AC, Holstege CP, Lee JK, Charlton NP.** The epidemiology of caving injuries in the United States. *Wild Environ Med*. 2012;23(3):215–222.
16. **Strohle M, Beeretz I, Rugg C, et al.** Canyoning accidents in Austria from 2005 to 2018. *Int J Environ Res Public Heal*. 2019;17(1):102.
17. **Wild FJ.** Epidemiology of mountain search and rescue operations in Banff, Yoho, and Kootenay National Parks, 2003-06. *Wild Environ Med*. 2008;19(4):245–251.
18. **Worley GH.** Civilian helicopter search and rescue accidents in the United States: 1980 through 2013. *Wild Environ Med*. 2015;26(4):544–548.
19. **Flinn SD.** On-field management of emergent and urgent extremity conditions. *Curr Sports Med Rep*. 2006;5(5):227–232.
20. **Auerbach P, Donner, HJ, Weiss, EA.** *Field guide to wilderness medicine*. 3rd ed. Mosby, Inc.; 2008.
21. **Irajpour A, Kaji NS, Nazari F, et al.** A comparison between the effects of simple and traction splints on pain intensity in patients with femur fractures. *Iran J Nurs Midwifery Res*. 2012;17(7):530–533.
22. **Tilton B, Hubbell, F.** *Medicine for the backcountry*. 3rd ed. Globe Pequot Press; 1999.
23. **Studer N, Grubbs S, Horn G, Danielson P.** Evaluation of commercially available traction splints for battlefield use. *J Spec Oper Med*. 2014;14(2):46–55.
24. **Melamed E, Blumenfeld A, Kalmovich B, et al.** Prehospital care of orthopedic injuries. *Prehosp Disaster Med*. 2007;22(1):22–25.
25. **McSwain NE, NAEMT Staff.** *PHTLS Prehospital Trauma Life Support: Military version*. 6th ed. Mosby/JEMS; 2007.
26. **Martin LKD, McBride LTJ, Unangst CA, Chisholm J.** Prospective study of military Special Operations medical personnel and lower extremity fracture immobilization in an austere environment. *Foot Ankle Orthop*. 2020;5(2):2473011420916144.

27. **Lee C, Porter KM.** Prehospital management of lower limb fractures. *Emerg Med J*. 2005;22(9):660–663.
28. **Robinson P, O'Meara M.** The Thomas splint: its origins and use in trauma. *J Bone Joint Surg Br*. 2009;91(4):540–544.
29. **Syme K.** Are you pulling my leg? Does the use of traction splints in the pre-hospital management of patients with femur fractures reduce the complications compared to traditional splinting? *Australas J Paramedicine*. 2020;17(1).
30. **Rowlands T, Clasper J.** The Thomas splint–A necessary tool in the management of battlefield injuries. *BMJ Mil Health*. 2003;149(4): 291–293.
31. **Thomas HO.** *Diseases of the hip, knee, and ankle joints, with their deformities, treated by a new and efficient method*. HK Lewis; 1878.
32. **Weichenthal L, Spano S, Horan B, Miss J.** Improvised traction splints: a wilderness medicine tool or hindrance? *Wild Environ Med*. 2012;23 (1):61–64.
33. **Sloan JP, Dove AF.** Inflatable splints—what are they doing? *Arch Emerg Med*. 1984;1(3):151–155.
34. **Schetrumpf JR**. Instant splints: vacuum compacted polystyrene balls. *Br J Plast Surg*.1973;26(4):393–397.
35. **Brown E, Rodenberg N, Amend J, et al.** Universal robotic gripper based on the jamming of granular material. *Proc Natl Acad Sci U S A*. 2010;107(44):18809–18814.
36. **Letts RM, Hobson DA.** The vacuum splint: an aid in emergency splinting of fractures. *Can Med Assoc J*. 1973;109(7):599–600.
37. **Wytch R, Mitchell C, Wardlaw D, et al.** Mechanical assessment of polyurethane impregnated fibreglass bandages for splinting. *Prosthet Orthot Int*.1987;11(3):128–134.
38. **Nackenson J, Baez AA, Meizoso JP**. A descriptive analysis of traction splint utilization and IV analgesia by emergency medical services. *Prehosp Disaster Med*. 2017;32(6):631–635.
39. **Mansson E, Ruter A, Vikstrom T.** Femoral shaft fractures and the prehospital use of traction splints. *Scand J Trauma Resusc Emerg Med*. 2006;14:26–29.
40. **Monga TN, Symington DC, Lowe P, Elkin N.** Load bearing and suspension characteristics of airsplint as a temporary prosthesis. *Prosthet Orthot Int*. 1985;9(2):100–104.
41. **Great B.** *Royal Army Medical Corps training, 1911*. London, H.M. Stationery Off.; 1911.
42. **Sexton MJ, Fyffe EL, Gaunt JK.** New improvised splint in place of rifle splint for fractures of the thigh. *J R Army Med Corps*. 1911;17(4): 392–395.
43. **Scotland T.** The First World War and its influence on the development of orthopaedic surgery. *JR Col. Physicians Edinb*. 2014;44(2):163–169.
44. **Wade H.** A British Medical Association lecture on the influence of the war on the modern treatment of fractures. *Brit Med J*. 1921;1(3140): 327–330.
45. **U.S. Special Operations Command.** *Special Operations Forces Medical Handbook*: 2020. https://www.jsomonline.org/jsomstorefront/ranger-medic-handbook-2022-updates?path=5. Accessed 18 September 2023.
46. **Chavasse FB.** Treatment of fractured femur at the site of the casualty. *Br Med J*. 1940;1(4122):25.
47. **Swanepoel S, Bonner B, Salence B, et al.** A guide to an improvised femoral traction splint in a resource-limited setting. *Afr J Emerg Med*. 2021;11(2):248–251.
48. **Tactical Combat Casualty Care Guidelines for Medical Personnel.** *Joint Trauma System Clinical Practice Guidelines*. 2019. https://jts.health.mil/index.cfm/PI_CPGs/cpgs. Accessed 18 September 2023.
49. **United States Marine Corps Field Medical Training Battalion.** FMSO 105 individual combat equipment. https://www.trngcmd.marines.mil/Portals/207/Docs/FMTBE/Student%20Materials/FMSO%20Manual/105.pdf. Accessed 18 September 2023.
50. **Hurt HF, Reilly AJ.** Improvised hydration bladder air splint: A wilderness case report. *Wild Environ Med*. 2019;30(1):86–89.
51. **Ellerton J, Tomazin I, Brugger H, Paal P, International Commission for Mountain Emergency Medicine.** Immobilization and splinting in mountain rescue. Official Recommendations of the International Commission for Mountain Emergency Medicine, ICAR MEDCOM, Intended for Mountain Rescue First Responders, Physicians, and Rescue Organizations. *High Alt Med Biol*. 2009;10(4):337–342.
52. **Sarmiento A.** Functional bracing of tibial and femoral shaft fractures. *Clin Orthop Relat Res*. 1972;82:2–13.
53. **Sarmiento A, McKellop HA, Llinas A, et al.** Effect of loading and fracture motions on diaphyseal tibial fractures. *J Orthop Res*. 1996;14 (1):80–84.
54. **Sarmiento A, Warren WD.** A re-evaluation of lower extremity amputations. *Surg Gynecol Obstet*. 1969;129(4):799–802.
55. **Sarmiento A, Latta LL.** Functional fracture bracing. *J Am Acad Orthop Surg*. 1999;7(1):66–75.
56. **Epari DR, Kassi JP, Schell H, Duda GN.** Timely fracture-healing requires optimization of axial fixation stability. *J Bone Joint Surg Am*. 2007;89(7):1575–1585.
57. **Claes L, Eckert-Hubner K, Augat P.** The effect of mechanical stability on local vascularization and tissue differentiation in callus healing. *J Orthop Res*. 2002;20(5):1099–1105.
58. **Rhinelander FW.** Tibial blood supply in relation to fracture healing. *Clin Orthop Relat Res*. 1974(105):34–81.
59. **Auguat P, Burger J, Schorlemmer S, et al.** . Shear movement at the fracture site delays healing in a diaphyseal fracture model. *J Orthop Res*. 2003;21(6):1011–1017.
60. **Schell H, Thompson MS, Bail HJ, et al.** Mechanical induction of critically delayed bone healing in sheep: radiological and biomechanical results. *J Biomech*. 2008;41(14):3066–3072.
61. **Sarmiento A, Sinclair WF.** Application of prosthetics-orthotics principles to treatment of fractures. *Artif Limbs*. 1967;11(2):28–32.
62. **Love FW, Polsky S, Barker HS, Rizzo PC.** An alternative to amputation for complicated fracture of the tibia. *Orthop Prosthet Appliance J*. 1964:192–195.
63. **Kay HW.** Clinical applications of the Veterans Administration prosthetics center Patellar-Tendon-Bearing brace. *Artif Limbs*. 1971;15(1): 46–67.
64. **King RE**. The Caldwell os calcis brace. *Orthopedic & Prosthetic Appliance Journal*. 1959:62–63.
65. **Lerman M.** Use of a Cast-Brace Application Device, Plaster Brim, and Ankle Support for Fracture Bracing. *Orthot Prosthet*. 1972:23–30.
66. **Ahlgren SA, Hultin J, Nilsson J, Westman L.** Orthoses for functional treatment of ankle fractures: A preliminary report. *Prosthet Orthot Int*. 1982;6(1):24–26.
67. **Lin CW, Moseley AM, Refshauge KM.** Effects of rehabilitation after ankle fracture: a Cochrane systematic review. *Eur J Phys Rehabil Med*. 2009;45(3):431–441.
68. **Shah KM.** Tibial shaft fractures: a biomechanical and clinical approach: Thesis summary. *Clin Biomech*. 1992;7(4):247–248.
69. **Santoni BG, Aira JR, Diaz MA, et al.** Radiographic evaluation of acute distal radius fracture stability: A comparative cadaveric study between a thermo-formable bracing system and traditional fiberglass casting. *Clin Biomech*. 2017;47:20–26.
70. **Tang SF, Au TL, Wong AM, Lee MY.** Modified fracture brace for tibial fracture with varus angulation: a case report. *Prosthet Orthot Int*. 1995;19(2):115–119.
71. **Bontis N, Drogonetti, N.** The knowledge toolbox: A review of the tools available to measure and manage intangible resources. *Eur Manag J*. 1911;17(4):391–402.
72. **Stills M.** Vacuum-formed orthosis for fracture of the tibia. *Orthot Prosthet*. 1976;30(2):43–55.
73. **Trepman E, Donnelly P.** Patellar tendon-bearing, patten-bottom caliper suspension orthosis in active Charcot arthropathy: crutch-free ambulation with no weight bearing in the foot. *Foot Ankle Int*. 2002; 23(4):335–339.
74. **Pretz R, Brown C, Hughes WB, Altschuler EL.** Maximizing functional mobility in an electrical burn patient using a patellar tendon bearing orthosis. *J Rehab Med*. 2016;48(7):636–638.
75. **Highsmith MJ, Nelson LM, Carbone NT, et al.** Outcomes associated with the Intrepid Dynamic Exoskeletal Orthosis (IDEO): A systematic review of the literature. *Mil Med*. 2016;181(S4):69–76.
76. **Franklin N, Hsu JR, Wilken J, et al.** Advanced functional bracing in lower extremity trauma: Bracing to improve function. *Sports Med Arthrosc Rev*.2019;27(3):107–111.
77. **Radcliffe CW.** Functional considerations in the fitting of above-knee prostheses. *Artif Limbs*. 1955;2(1):35–60.
78. **Sabolich J.** Contoured adducted trochanteric-controlled alignment method (CAT-CAM): Introduction and basic principles. *Clin Prosth Orthos*. 1985;9:15–26.
79. **Bergmann G, Correa da Silva M, Neff G, et al.** Evaluation of ischial weight-bearing orthoses, based on in-vivo hip joint force measurements. *Clin Biomech*. 1994;9(4):225–234.
80. **Beech Z, Parker P.** Internal fixation on deployment: never, ever, clever? *J R Army Med Corps*.2012;158(1):4–5.
81. **Johnson CT, Wroe JA, Agarwal R, et al.** Hydrogel delivery of lysostaphin eliminates orthopedic implant infection by Staphylococcus aureus and supports fracture healing. *Proc Natl Acad Sci U SA*. 2018; 115(22):E4960–E4969.

PMID: 37733954; *DOI:* 10.55460/QM3U-JZB1

The Special Operations Medical Association's Official Journal

JSOM

Fall 2023
Volume 23, Edition 3

JOURNAL *of* SPECIAL OPERATIONS MEDICINE™

THE JOURNAL FOR OPERATIONAL MEDICINE AND TACTICAL CASUALTY CARE

Inside this Issue:

- FEATURE ARTICLES: DripAssist and Traditional Methods for Rate Infusions
- Military Physician Telemedicine in Turkey
- SOF Cognitive Assessments
- WWII Yugoslav Guerrilla Hospital
- Combat Vascular Access
- Intranasal Analgesia in French Armed Forces
- Psychological Strategies in EOD Technicians
- IV Infusion of a DCR Cocktail Decreases Blood Loss in a Pig Model
- Unconventional Resilience
- Artificial Blood Development
- Rib Fracture POC Ultrasound & Pain Control
- Sympathoadrenal Activity in Cold Water Diving
- CASE REPORT: Phosphorus Burn Management
- ONGOING SERIES: Human Performance Optimization, Prolonged Casualty Care, Book Review, TECC for TEMS Updates, TCCC Updates, *and more!*

Dedicated to the Indomitable Spirit, Lessons Learned & Sacrifices of the SOF Medic

A Peer Reviewed Journal That Brings Together The Global Interests of Special Operations' First Responders