Bilateral Pneumothoraces in a Tandem Parachuting Passenger Without Traumatic Impact

A Case Report

Preston J. Fedor, MD[1]; Brian Riley, MA[2]; Daniel A. Fowl, NRP[3]; Anthony Donahue, NRP[4]*

ABSTRACT

In parachuting, orthopedic and head injuries are well-documented risks associated with the parachute deployment and landing phases. Thoracic injuries have only been seen on rare occasion in conjunction with direct impact trauma. In this report, we detail a case of a young, healthy, tandem skydiving passenger who suffered bilateral pneumothoraces with delayed symptom onset, with no identifiable injury during the jump or landing. Exploring the forces of the parachute "opening shock," we suggest a plausible compressive mechanism for this novel presentation, as well as briefly discuss the options for diagnosis and conservative management of pneumothorax in the operational context. While this is an exceedingly rare event, pneumothorax should be considered in patients complaining of thoracic symptoms following a skydive.

KEYWORDS: *pneumothorax; prolonged field care; military medicine; prehospital ultrasound; parachute injuries; parachuting*

Introduction

Parachuting is an activity with inherent and well-documented risks. The worldwide injury rates are variable in the literature with rates of 1.5–18.8/1000 civilian jumps and 2.2–19.7/1000 for the military. However, there are minimal data specifically concerning tandem parachuting injury rates.[1–8] In a small United Kingdom study of parachute injuries presenting to a single Emergency Department (ED), 17% of injuries were the result of tandem jumps. A forensic case series of all 24 parachuting deaths in Arizona over a 15-year period identified only 1 death from tandem skydiving (Figure 1).[9]

Lower extremity orthopedic injuries and head trauma are common with landing, accounting for up to 90% of documented injuries.[6,7,10] Upper extremity, back, and neck injuries are most often sustained in other phases of the jump, commonly while exiting the aircraft and during parachute opening.[6] Thoracic injuries are exceedingly rare in nonfatal mishaps and only reported in large parachuting case series and two case reports.[1,3,10]

We report the first known case of bilateral pneumothoraces sustained from tandem parachuting without traumatic impact or acute symptom onset during the event. We present a possible compressive mechanism and discuss considerations for diagnosis and conservative treatment in the operational context.

FIGURE 1 *Example of military parachuting.*

Case Presentation

A previously healthy 20-year-old man presents to the emergency department with three days of chest discomfort and shortness of breath. Twelve hours prior to symptom onset, he made a skydive as a tandem passenger for the first time, which was uneventful. He denied striking his chest, landing awkwardly, or feeling discomfort at any time. He was asymptomatic before, during, and immediately after the jump and landing. The morning after his jump, the patient awoke with a sharp pain in his chest and intermittent shortness of breath. He was unable to go to work due to these symptoms. Over the next 2 days, symptoms progressed to dyspnea with exertion, constant fatigue, and diffuse chest discomfort, which was heavy and sharp in nature, with no radiation and worse with torso movement. He did not have any associated fever, chills, cough, palpitations, edema, bruising, or rib or chest wall pain.

The patient was referred to the ED by his primary care physician (PCP) after a telephone appointment. En route, he stopped to have an outpatient chest x-ray (CXR) as ordered by the PCP, which was not read prior to ED arrival. Bilateral pneumothoraces were noted by the emergency physician and the

*Correspondence to preston.fedor@us.af.mil

[1]**Maj Preston J. Fedor** is an emergency medicine and EMS physician and a United States Air Force (USAF) pararescue flight surgeon in the 920th Rescue Wing. [2]**Maj Brian Riley** is a USAF Combat Rescue Officer in the 920th Rescue Wing, USPA tandem skydiving instructor, and medical student at the University of Washington School of Medicine. [3]**TSgt Daniel A. Fowl** is a USAF Pararescueman (PJ) in the 920th Rescue Wing and a medical student at the University of the Incarnate Word School of Osteopathic Medicine. [4]**TSgt Anthony Donahue** is a USAF PJ in the 920th Rescue Wing and a researcher studying psychedelic-assisted psychotherapy at Harvard Medical School.

subsequent radiology interpretation found "moderate sized right apical pneumothorax with a smaller left apical pneumothorax; no pleural effusion or rib fractures" (Figure 2).

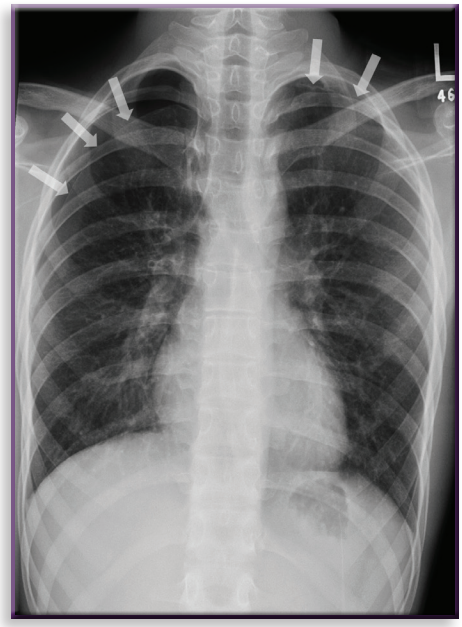

FIGURE 2
Representative chest radiograph; arrows mark borders of bilateral pneumothorax.

Case courtesy of Dr Hani Makky Al Salam, Radiopaedia.org, rID: 12353

This patient had no past medical history, relevant family history, history of chest trauma or instrumentation, or prior pneumothorax. He has never been diagnosed with Marfan syndrome. He denied history of smoking and was taking no medications. Surgical history was only remarkable for a surgery to the left shoulder many years prior.

Vital signs at triage were blood pressure 146/83, heart rate 80, respiratory rate 22, oxygen saturation 100%, temperature 36.8°C. He was tall and slim with a height of 1.85 m and weight of 63.5 kg (body mass index 18.6). On examination, the patient was noted to be in no distress and was speaking in complete sentences. He was mildly tachypneic. Lungs were clear bilaterally, but diminished breath sounds were noted anteriorly on the right. No subcutaneous emphysema was palpable. No chest wall or rib tenderness was elicited. No ecchymosis was noted. Heart was regular rate and rhythm without murmur. The remainder of his exam was unremarkable.

The patient was placed on oxygen via non-rebreather mask at 15 liters per minute according to local standard of care. A thoracic surgeon was consulted who recommended the patient be admitted to the medical floor with continued oxygen by facemask and a repeat CXR the following day. The surgeon estimated the right sided pneumothorax to be 10% of the lung volume. Neither chest tube nor aspiration were indicated given the size of the pneumothoraces and the patient's clinical stability.

Twenty-four hours later, a follow-up portable single-view CXR demonstrated an unchanged right pneumothorax and a "barely perceptible" left pneumothorax, and his vital signs (including a room air oxygen saturation of 100% at the time of reassessment and discharge) remained stable. He was discharged home and followed up in clinic with the thoracic surgeon as scheduled 2 weeks later. At that time, the patient was doing well with no residual nor new complaints. A repeat CXR in clinic showed no residual pneumothorax. A review of the electronic medical record showed no additional encounters in the following year.

Discussion

Chest injuries from parachuting are rarely reported in nonfatal mishaps. One study of 117,000 jumps reported two thoracic injuries out of 2,204 total injuries, and only one of the two required evaluation in the ED.[1] In a study of 141 injuries sustained during military freefall school, three chest injuries were noted; the manuscript did not include additional details of the injuries.[11] A review of parachuting injuries from over 176,000 jumps reported the following percentages of chest injuries: chest contusion (0.6%), sternum fracture (0.1%), and rib fracture (1.3%). Pneumothorax was not specifically mentioned in these data nor did the authors differentiate between solo and tandem parachuting injuries.[10]

There are case reports documenting unilateral pneumothorax due to direct impact trauma while parachuting. In one case, an American paratrooper struck his chest during a hard parachute landing fall (PLF) and suffered a small apical pneumothorax that was treated with a chest tube.[12] Another case describes bilateral pneumothoraces, contusions, and multiple other injuries as the result of an Indian paratrooper disconnecting his parachute 100 feet in the air and impacting the surface of the ocean after a brief freefall.[13]

Possible Mechanism of Injury

Clearly, a definitive mechanism of injury cannot be determined by a single case report. We present a plausible potential mechanism here based on the available literature and the authors' experience to encourage further discussion and additional research. The patient did not feel discomfort or dyspnea during the event or later that day; symptoms began about 12 hours later. The patient reported an uneventful airplane exit, freefall, canopy opening, and landing without any direct impact. Therefore, the phase of the jump most likely to have caused the pneumothoraces was canopy opening when he would have experienced the abrupt deceleration known as the "opening shock."

According to the British Parachute Association, during parachute deployment, a skydiver experiences "a brisk deceleration, usually about 4*g* but occasionally in excess of 15*g* and with a rapid onset."[14] The skydiver is pulled from a horizontal ("belly to earth") position into a vertical ("feet to earth") orientation under the inflating parachute. The higher forces of a "hard-opening" most closely resemble a whiplash mechanism as the head and cervical spine experience a rapid hyperextension and then flexion.[14] A "hard-opening" during a tandem jump can be the result of parachute packing technique, drogue parachute failure, or parachute deployment at a terminal velocity above 120 mph.[15,16] In this case study, we could not determine if the tandem pair experienced a hard-opening, as first-time skydivers do not have a basis for comparison to a normal parachute opening force, and the instructor had no memory of this jump.

A case report published in 2011 reported a dissection of the left anterior descending coronary artery in a 35-year-old BASE jumper after a "hard-opening." This demonstrated that parachute deployment has the ability to deliver enough energy to cause intrathoracic injury.[17] In tandem skydiving, the

compressive effect of the harness can be more severe than solo skydiving as the passenger is essentially squeezed between the chest strap in front and the tandem instructor behind. This force distribution on the chest is most analogous to that of the load distributing band type of mechanical CPR device, which has been shown to cause pneumothoraces, rib fractures, and subcutaneous emphysema (Figure 3).[18]

FIGURE 3
Tandem passenger harness.

Inexperienced tandem passengers may hold their breath during the overwhelming experience of the skydive or be caught off guard by the surprise of the parachute deployment. Against a closed glottis, this creates a closed system in the chest that amplifies the effects of thoracic pressure from circumferential chest compression. The increased alveolar pressure caused by valsalva has been previously associated with spontaneous pneumothorax, which supports this mechanism.[19,20] As described in an *Annals of Surgery* article from 1941, "Forced expiration with the glottis closed raises the intra-pulmonic pressure. A crushing pressure applied to the chest, as may happen in accidents, can raise it to such an extent that one or both lungs may be ruptured, even though the thorax is not penetrated."[21] It is unclear whether a Valsalva played a role in this case.

We believe the most likely mechanism of injury to be a rapid chest compression during the opening shock of parachute deployment. It is unlikely the patient arrived to the skydive already harboring small bilateral pneumothoraces. If this were the case, he would likely have become symptomatic during the flight to jump altitude as the trapped air expanded with decreasing atmospheric pressure in accordance with Boyle's law.[22] Equally improbable would be spontaneous pneumothoraces coincidentally occurring the day after his jump. Although not diagnosed with Marfan syndrome, his tall and thin stature and male sex are risk factors for pneumothorax and could have made his lungs more susceptible to the compressive trauma of the opening shock. He did not report any other pneumothorax risk factors such as smoking, vaping, genetic predisposition, underlying lung disease (i.e., asthma, COPD, cystic fibrosis, malignancy, infection), cocaine inhalation, recent air travel or scuba diving, prior pneumothorax, or thoracic trauma.[23]

Operational Considerations in the Evaluation and Management of a Pneumothorax

In the event a military parachutist or tandem passenger presented with thoracic trauma and signs and symptoms of a significant pneumothorax or tension pneumothorax, they should be treated emergently.[24] However, if there is a subacute presentation in a stable patient, observation with or without oxygen supplementation can be considered. Up to 80% of small pneumothoraces (<15% of pleural volume) will not further accumulate or recur when managed conservatively.[25] The rate of resorption can be increased by a factor of four with the administration of 100% oxygen. If the patient has stable to improving symptoms or findings on repeat CXR or ultrasound, no further intervention is necessary.[26] The proximity of definitive care, availability of resources in the field, and other mission specific factors should be considered, but the patient may not require emergent evacuation.

If available, an ultrasound can be performed to estimate the extent of the pneumothorax and look for presence of blood in the pleural space. Serial ultrasounds can demonstrate changes in size and inform treatment trajectory.[27] Research on prehospital ultrasonography shows this modality is effective for field evaluation and logistical management of the patient, and can aid destination decision-making and transport priority.[28] In many studies both in the trauma center and prehospital settings, ultrasound was better at detecting pneumothorax than a CXR.[27–29] In one case, a tube thoracostomy was avoided in a combat casualty with penetrating injuries when a pulmonary ultrasound at the Role 1 demonstrated signs of normal pleural sliding.[30]

An extended focused assessment with sonography in trauma (E-FAST) is an efficient tool for identifying pneumothoraces and other critical injuries in the combat setting. With appropriate training, this field-expedient diagnostic can be completed in 2–3 minutes.[31]

If the patient is stable with a relatively large pneumothorax, or a smaller pneumothorax that is getting progressively larger, a needle aspiration can expedite reinflation of the lung, improvement of clinical symptoms, and return to the mission.[32] However, there is an increased risk of iatrogenic lung injury with smaller amounts of air between the pleura. With insertion of the catheter-over-needle into the pleural space (as in a needle decompression), air can be aspirated with a syringe in a one-time procedure, or the catheter can be left in place and connected to a Heimlich valve or three-way stopcock for ongoing drainage.[32] If there is a persistent leak or worsening symptoms, the patient should be prioritized for evacuation to the nearest medical facility, and consideration for an open or tube thoracostomy made (depending on provider scope of practice) prior to prolonged transport or flight.[26,32]

In an operational setting, depending on the level of practitioner comfort and resources, both needle aspiration and observation with high-flow oxygen are reasonable management strategies for a stable subacute pneumothorax. These conservative approaches could avoid mission-compromising extraction of an operator from the field and the added complexity of managing a chest tube in a prolonged field care scenario.

Conclusion

Pneumothorax is a rarely documented complication of parachuting activities, but it is possible with direct impact trauma

or thoracic compression from the opening shock of parachute deployment. If a military member presents with chest discomfort, shortness of breath, dyspnea on exertion, pleurisy, or other concerning thoracic symptoms during or after parachuting, this diagnosis should be considered. Pneumothorax can accurately be diagnosed and followed by point of care ultrasound in the field. Many uncomplicated pneumothoraces can be conservatively managed with close monitoring and oxygen alone, or with simple needle aspiration resulting in resolution of symptoms and low risk of recurrence.

Disclosures

The authors have nothing to disclose.

References

1. **Barrows TH, Mills TJ, Kassing SD.** The epidemiology of skydiving injuries: world freefall convention, 2000–2001. *J Emerg Med*. 2005;28(1):63–68.
2. **Ellitsgaard N.** Parachuting injuries: a study of 110,000 sports jumps. *Br J Sports Med*. 1987;21(1):13–17.
3. **Dawson M, Asghar M, Pryke S, Slater N.** Civilian parachute injuries; 10 years on and no lessons learned. *Injury*. 1998;29(8): 573–575.
4. **Westman A, Björnstig U.** Fatalities in Swedish skydiving. *Accid Anal Prev*. 2005;37(6):1040–1048.
5. **Craig SC, Lee T.** Attention to detail: injuries at altitude among U.S. Army Military static line parachutists. *Mil Med*. 2000;165(4): 268–271.
6. **Ekeland A.** Injuries in military parachuting: a prospective study of 4499 jumps. *Injury*. 1997;28(3):219–222.
7. **Knapik JJ, Steelman R, Grier T, et al.** Military parachuting injuries, associated events, and injury risk factors. *Aviat Space Environ Med*. 2011;82(8):797–804.
8. **Farrow GB.** Military static line parachute injuries. *Aust N Z J Surg*. 1992;62(3):209–214.
9. **Cronin R, Winston DC.** Parachute deaths in Southern Arizona. *Acad Forensic Pathol*. 2017;7(4):649–656.
10. **Bricknell MCM, Craig SC.** Military parachuting injuries: a literature review. *Occup Med*. 1999;49(1):17–26.
11. **Glorioso JE, Batts KB, Ward WS.** Military free fall training injuries. *Mil Med*. 1999;164(7):526–530.
12. Woo C, Berry-Caban C, Norland S, Skinner D, Motyka T, McKiernan S. Case study: traumatic pneumothorax after parachute landing. *J Pulm Respir Med*. 2018;08(03). doi:10.4172/2161-105X.1000461
13. **Tyagi R, Kumar S, Deshmukh P, Sivasankar R.** Pulmonary barotrauma in a paratrooping accident. *Med J Armed Forces India*. 2019;75(3):347–349.
14. British Parachute Association. Student tandem parachutist request for medical advice. *BPA Form 115B*. 2016;4(1):1.
15. Uninsured United Parachute Technologies. *Sigma Tandem Systems owners manual* - MAN-013, Rev 0.5. 5 September 2019. https://uptvector.com/wp-content/uploads/2018/08/Manual_Sigma_MAN-013.pdf. Accessed 24 January 2022.
16. **Crouch J.** Whack! You're Open! - Preventing hard openings. *Parachut Mag*. February 2003. http://www.parachute.ch/Bilder/Parachutist%20Article%20on%20Preventing%20Hard%20Openings.htm. Accessed 24 January 2022.
17. **Brugger N, Saguner AM, Zbinden S, Khattab AA.** LAD dissection following parachute belt trauma during BASE jumping. *Int J Cardiol*. 2012;159(2):e25–e26.
18. **Wik L, Olsen J-A, Persse D, et al.** Manual vs. integrated automatic load-distributing band CPR with equal survival after out of hospital cardiac arrest. The randomized CIRC trial. *Resuscitation*. 2014;85(6):741–748.
19. **Birrer RB, Calderon J.** Pneumothorax, pneumomediastinum, and pneumopericardium following Valsalva's maneuver during marijuana smoking. *N Y State J Med*. 1984;84(12):619–620.
20. **Dejene S, Ahmed F, Jack K, Anthony A.** Pneumothorax, music and balloons: A case series. *Ann Thorac Med*. 2013;8(3):176.
21. **Elkin DC, Harris MH.** Injuries to the chest. *Ann Surg*. 1942;113 (5):688–696.
22. **Knotts D, Arthur AO, Holder P, et al.** Pneumothorax volume expansion in helicopter emergency medical services transport. *Air Med J*. 2013;32(3):138–143.
23. **Plojoux J, Froudarakis M, Janssens J-P, et al.** New insights and improved strategies for the management of primary spontaneous pneumothorax. *Clin Respir J*. 2019;13(4):195–201.
24. **Butler FK, Holcomb JB, Shackelford S, et al.** Management of suspected tension pneumothorax in Tactical Combat Casualty Care: TCCC Guidelines change 17-02. *J Spec Oper Med*. 2018;18(2): 19–35.
25. **O'Rourke JP, Yee ES.** Civilian spontaneous pneumothorax. Treatment options and long-term results. *Chest*. 1989;96(6): 1302–1306.
26. **Arshad H, Young M, Adurty R, Singh AC.** Acute pneumothorax. *Crit Care Nurs Q*. 2016;39(2):176–189.
27. **Ketelaars R, Hoogerwerf N, Scheffer GJ.** Prehospital chest ultrasound by a Dutch helicopter emergency medical service. *J Emerg Med*. 2013;44(4):811–817.
28. **van der Weide L, Popal Z, Terra M, et al.** Prehospital ultrasound in the management of trauma patients: Systematic review of the literature. *Injury*. 2019;50(12):2167–2175.
29. **Galbois A, Ait-Oufella H, Baudel J-L, et al.** Pleural ultrasound compared with chest radiographic detection of pneumothorax resolution after drainage. *Chest*. 2010;138(3):648–655.
30. **Roberts J, McManus J, Harrison B.** Use of ultrasonography to avoid an unnecessary procedure in the prehospital combat environment: a case report. *Prehosp Emerg Care*. 2006;10(4):502–506.
31. **Husain LF, Hagopian L, Wayman D, et al.** Sonographic diagnosis of pneumothorax. *J Emerg Trauma Shock*. 2012;5(1):76.
32. **Baumann MH, Strange C, Heffner JE, et al.** Management of spontaneous pneumothorax: an American College of Chest Physicians Delphi consensus statement. *Chest*. 2001;119(2):590–602.

The Special Operations Medical Association's Official Journal

JSOM

Fall 2022
Volume 22, Edition 3

JOURNAL *of* SPECIAL OPERATIONS MEDICINE™

THE JOURNAL FOR OPERATIONAL MEDICINE AND TACTICAL CASUALTY CARE

Inside this Issue:

- FEATURE ARTICLES: Effect of Airdrop on Fresh and Stored Whole Blood
- Nursing: Mild TBI Inpatient Rehab › Whole Blood Storage in Austere Environments
- Active Warfighter Resilience › Unorthodox Training Methods
- Military GME Special Operations Clinicians
- Stressful Simulation Training in Swedish Special Forces
- Solo-T and the Combat Application Tourniquet Evaluation › Deployed Helicopter Crashes
- Pioneer: Edith Nourse Rogers › Training Military Nurses for Point-of-Care Ultrasound
- CRITICAL CARE MEDICINE: Acute Kidney Injury
- IN COMMEMORATION OF: Women in US Military History
- CASE REPORTS: Walking Quadriplegic › Operational Consideration for Airway Management
- Bilateral Pneumothoraces in a Tandem Parachuting Passenger › Hypertonic Saline for Severe TBI
- EDITORIALS: Military Physician Leadership › Neurological Directed-Energy Weapons for Military Medicine
- Letter to the Editor › 2022 SOMSA Abstracts
- ONGOING SERIES: Human Performance Optimization, Infectious Diseases, Psychological Performance, TCCC Updates, *and more!*

Dedicated to the Indomitable Spirit, Lessons Learned & Sacrifices of the SOF Medic

A Peer Reviewed Journal That Brings Together The Global Interests of Special Operations' First Responders