Needle Thoracentesis Decompression: Observations From Postmortem Computed Tomography and Autopsy

H. Theodore Harcke, MD; Robert L. Mabry, MD; Edward L. Mazuchowski, MD

ABSTRACT

Background: Needle thoracentesis decompression (NTD) is a recommended emergency treatment for tension pneumothorax. Current doctrine recognizes two suitable sites: the second intercostal space in the midclavicular line and the fourth or fifth intercostal space in the anterior axillary line. **Methods:** A review was conducted of postmortem computed tomography and autopsy results in 16 cases where NTD was performed as an emergency procedure. **Results:** In 16 cases with 23 attempted procedures, the outcome was confirmed in 17 attempts. In 7 placements, the catheter was in the pleural cavity; in 7 placements, the catheter never entered the pleural cavity; and in 3 placements, cavity penetration was verified at autopsy even though the catheter was no longer in the cavity. Success was noted in 6 of 13 anterior attempts and 4 of 4 lateral attempts, for an overall success rate of 59% (10 of 17). In the remaining 6 attempted procedures, a catheter was noted in the soft tissue on imaging; however, presence or absence of pleural cavity penetration was equivocal. All placements were attempted in the combat environment; no information is available about specifically where or by whom. **Conclusion:** NTD via a lateral approach was more successful than that via an anterior approach, although it was used in fewer cases. This supports the revision of the Tactical Combat Casualty Care Guidelines specifying the lateral approach as an alternative to an anterior approach.

KEYWORDS: *needle thoracentesis decompression, Tactical Combat Casualty Care Guidelines, tension pneumothorax*

Introduction

Tension pneumothorax (TPTX), which is rare in the civilian trauma setting, is a common occurrence on the battlefield, where penetrating and explosion-related injuries are the most common mechanisms.[1,2] Recognition and management of TPTX are important facets of tactical combat casualty care, and great effort is made to prepare medical providers with the knowledge and skills to diagnose and treat the condition. TPTX is a life-threatening condition. If not corrected, circulatory collapse, shock, and death can rapidly occur. Prehospital therapy of choice is NTD. Currently NTD is recommended by the Committee on Tactical Combat Casualty Care as a Combat Lifesaver, Combat Medic, and Combat Paramedic level skill.

All initial-entry U.S. Army medics receive 2 hours of classroom instruction on the management of chest injuries including TPTX followed by 4 hours of hands-on NTD practice using a plastic manikin of a human thorax. Eight additional hours of hands-on "trauma lanes" training also includes NTD as well as other key life-saving interventions during simulated trauma scenarios.

Medical kits for all services contain a needle decompression device (NSN: 6515-01-541-0635). This is a 14-gauge × 3.25-inch flexible angiocatheter and rigid central metal needle introducer. The size of the device used by the military is based on a study of chest wall thickness in Servicemembers.[3]

Tactical Combat Casualty Care (TCCC) Guidelines state to "decompress the chest on the side of the injury with a 14-gauge, 3.25 inch needle/catheter unit inserted in the second intercostal space at the midclavicular line. Ensure that the needle entry into the chest is not medial to the nipple line and is not directed towards the heart." The newest version of the guideline also includes another option: "An acceptable alternate site is the fourth or fifth intercostal space at the anterior axillary line (AAL)."[4,5]

Our impetus to review placements of NTD devices was promped by a case with autopsy findings at the Office of the Armed Forces Medical Examiner (OAFME), Armed Forces Medical Examiner System, Dover AFB, Delaware, in which medical intervention included four NTD placements in the left hemithorax (Figure 1). We have incorporated findings from this case with others from OAFME to provide this report of NTD performed in the combat environment.

Figure 1 **(A)** *Autopsy photograph shows two needle thoracentesis catheters in the upper left chest and two lateral attempts with the catheters no longer present (arrows). Nipple lines are shown as dashed lines.* **(B)** *Neither anterior catheter entered the pleural cavity (arrowhead).* **(C)** *Both lateral attempts were confirmed to have entered the pleural cavity (open arrows).*

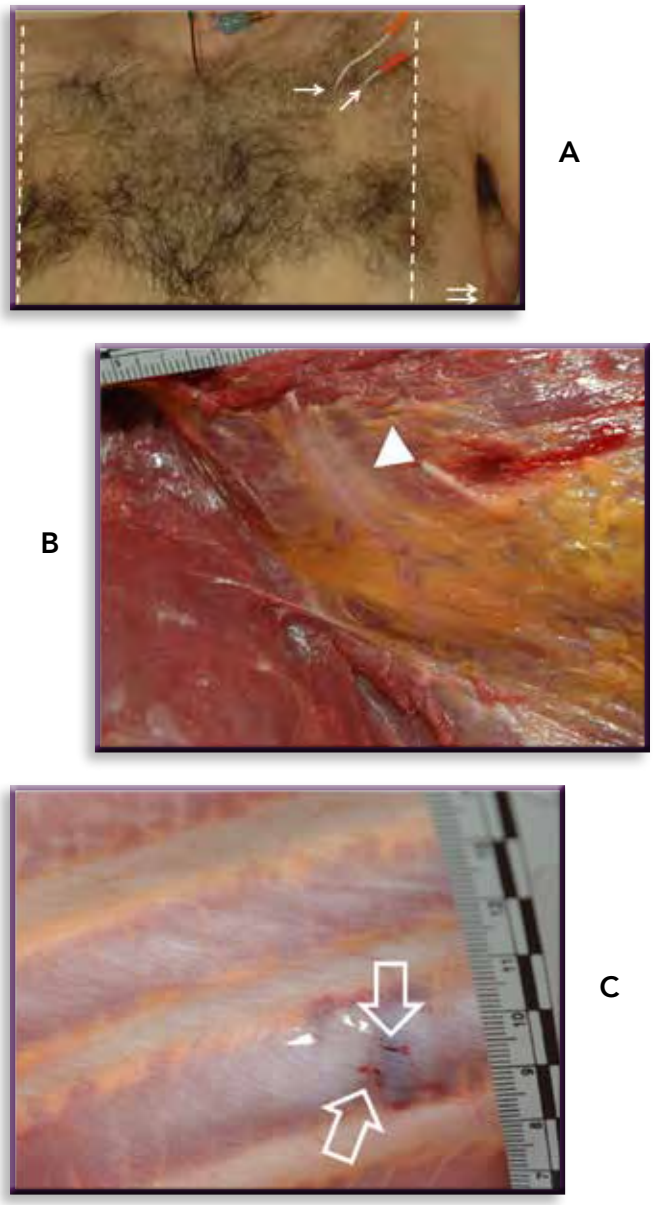

Methods and Materials

All deaths in theater that occurred during Operation Iraqi Freedom (OIF), Operation New Dawn (OND), and Operation Enduring Freedom (OEF) undergo an autopsy procedure by the OAFME at their facility at Dover AFB, Delaware. Included in the autopsy protocol is total body computed tomography (CT). The postmortem CT scan affords opportunity to assess any medical interventions that were undertaken. At the time of autopsy, CT findings are correlated with autopsy findings.[3,6] Selection of cases included in this retrospective study required that there was at least one NTD attempt with a catheter noted on imaging.

Axial CT scans were used to reconstruct multiplanar and three-dimensional images that showed the location of the NTD catheter entry, course and configuration of the device, and position at the time of scan. At autopsy, the course of the angiocatheter was studied to determine the presence or absence of penetration of the parietal pleura.

Results

Sixteen autopsied cases with NTD catheters present at the time of postmortem examination were identified. In 11 cases, a single catheter was present. Four cases had two catheters present, and in an additional case with two catheters, two needle puncture sites existed where NTD was attempted but a catheter was no longer present (this is the index case mentioned in the Introduction). This affords assessment of 23 attempts.

In seven placements, the NTD catheter was in the pleural cavity, per CT and autopsy analysis (Figure 2). In one placement, the NTD catheter was not located in the pleural cavity on CT, but autopsy showed that chest wall penetration had occurred. In two placements where the NTD catheter was not present, autopsy showed parietal pleura punctures, indicating chest wall penetration had occurred (Figures 1B, 1C). Therefore, 10 attempts can be considered successful.

Figure 2 *Axial computed tomography confirms needle thoracentesis catheter with core needle in place is positioned in the pleural cavity. There was a thoracotomy performed after placement.*

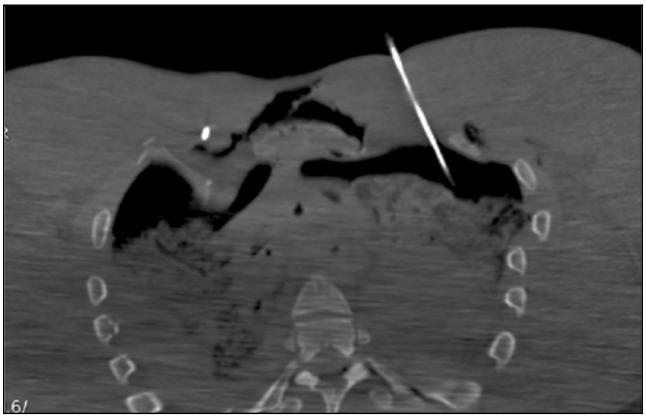

In 10 placements where the NTD catheter was not in the pleural cavity on CT, autopsy showed no penetration in 7 (Figure 3). Therefore, 7 attempts can be considered unsuccessful. There were 6 additional placements where the NTD catheter was not in the pleural cavity

Figure 3 *Unsuccessful attempt at needle decompression.* **(A)** *Computed tomography three-dimensional (3D) surface rendering shows the angiocatheter entry in relation to the nipple and mid-clavicular line.* **(B)** *Oblique 3D reconstruction of the catheter shows it curving lateral and downward, away from the third anterior rib.*

A

B

Figure 4 *Two successful needle thoracentesis placements from a lateral/anterior axillary line approach.* **(A)** *Right-sided catheter placement between the fourth and fifth ribs.* **(B)** *Left-sided placement between the fifth and sixth ribs;* **(C)** *note the curved configuration of the catheter in (B) on the oblique three-dimensional computed tomography reconstruction.*

A

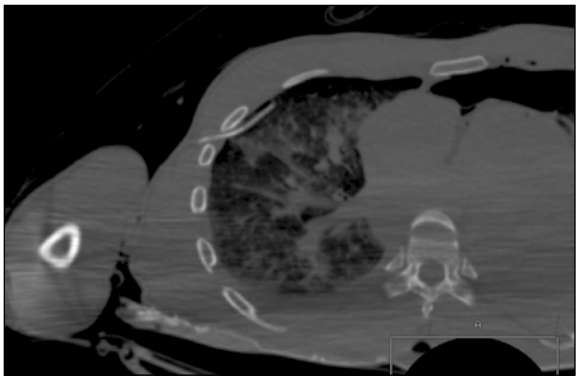

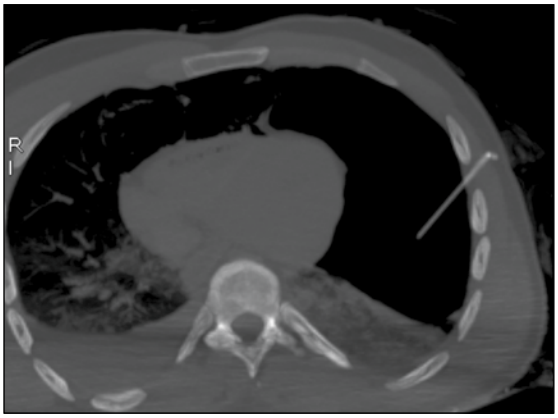

B

C

on CT; but at autopsy, no conclusion regarding presence or absence of catheter penetration could be made, and these attempts could not be included in the analysis.

Of the 17 NTD attempts where the catheter position and/or track could be documented, pleural cavity entry was noted in 10, for a 59% success rate. Thirteen attempts used an anterior approach: 6 successfully entered the pleural cavity, and 7 did not. Four attempts used a lateral approach, and all 4 entered the pleural cavity (Figure 4).

The NTD entry locations were varied with regard to rib space and the nipple line. Figure 5 depicts approximate surface locations of NTD placements and indicates that attempts on both right and left sides were unsuccessful in the anterior upper chest regions. There is a tendency for the entries to project above the second ribs; however,

this diagram does not show catheter direction and does not reflect a catheter striking a rib if this occurred. Discounting the intentional lateral placements, 11 of 13 placements were medial to their respective nipple line (Figures 1, 5).

Figure 5 *Schematic representation of the anterior chest showing locations where needle thoracentesis was attempted. Solid circles represent a confirmed successful attempt, and open circles show entry location of an unsuccessful attempt. For reference, the nipples have been marked by dashed circles.*

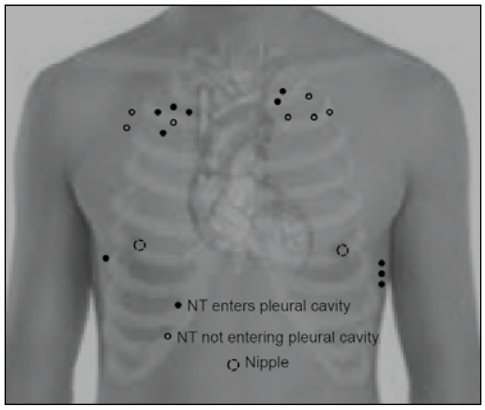

Angiocatheters without the core needle present often showed a curved configuration on CT scans. In some instances, it was associated with a rib, suggesting that the rib may have been encountered during insertion (Figure 6).

Discussion

Because NTD is potentially a lifesaving procedure, it is important to know how accurately it is performed by first responders and emergency care providers. The procedure may be unsuccessful for reasons that relate to training and technique, conditions (e.g., no or low light) encountered during placement, or to the device itself, such as improper length or kinking. While the literature has noted catheter length to be an important element in failure of needle decompression,[7,8] it was not a factor in our cases. The change to 8cm angiocatheters from 5-cm angiocatheters based on published chest wall thickness data[3] appears to have eliminated this cause for an unsuccessful NTD.

In the 23 attempts within this study, we could document 17 placements with certainty. We excluded 6 placements where the catheter was not in the chest cavity on imaging and at autopsy. It was not possible to rule out the possibility that penetration into the pleural cavity occurred and the catheter was pulled back or moved during transport. Due to the standard technique used to remove the chest plate at autopsy, it is often difficult to visualize a puncture mark of the parietal pleura of the anterior chest wall.

Figure 6 **(A)** *Axial computed tomography shows an unsuccessful needle thoracentesis attempt with the angiocatheter curving laterally from the second anterior rib.* **(B)** *The oblique three-dimensional reconstruction of the catheter suggests the deviation may have been caused by the catheter striking the rib during insertion.*

A

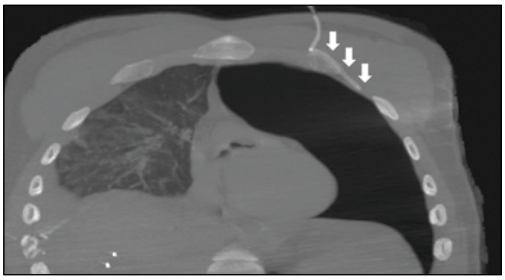

B

Anterior NTD attempts constitute the majority of the placements (13 of 17), which would be expected because, until recently, this was the recommended location. Right and left anterior placements were balanced, with 7 and 6, respectively. The success rate was higher for right attempts: 4 of 7 right and 2 of 6 left. It is notable that the few lateral placements documented were all successful (4 of 4). Others have also reported that correct needle placement is more likely to occur with lateral NTD than with anterior placement.[9] Ability to correctly locate the second intercostal space, mid-clavicular line has been noted to be more difficult than locating the fourth or fifth intercostal space in the AAL.[10] It is not unexpected that landmark identification is extremely difficult on the battlefield. Even emergency physicians had trouble identifying correct needle thoracentesis landmarks under elective conditions.[11] The medic has to operate in a hostile environment and contend with the casualty's equipment, body armor, and clothing.

The current guideline states "ensure needle entry into the chest is not medial to the nipple line" and appears to

represent difficulty for the providers. A report by Tien et al.[12] noted in seven cases that needle decompression was performed too medially, more than 2 cm medial to the mid-clavicular line. No reference was made to how these related to the nipple line. Only 2 of the 13 anterior placements were lateral to the nipple line (Figure 5), and both of these were unsuccessful attempts. When looking at the nipple line for our cases, we found that the nipples were widely spaced, as illustrated in Figure 1. Our cases suggest a small amount of space is lateral to the nipple line; this would be made more difficult to work in when the casualty is clothed. Anatomic variation and difficulty in accurately determining the position of the mid-clavicular line under the duress of combat may account for these instances. Consideration of a more effective method to determine proper anterior placement is likely needed. As more data such as these become available, AAL placement may prove superior and pose less risk of complications than anterior placement. Theoretical concerns about anterior axillary line placement include possible occlusion by the patient's arm and the difficulty of monitoring the catheter during litter packaging and transport.

Catheter kinking has been noted as a reason for NTD failure.[13] Although we did not observe kinking directly, we did note curvature of the catheter in three of the unsuccessful attempts. In most instances, the CT scans suggest that deviation is related to striking a rib at time of initial placement (Figure 6). Was the response to striking a rib to withdraw the core needle, while advancing the flexible angiocatheter? This process of advance/withdrawal is part of the prescribed technique for vascular angiocatheter insertion and may be a reflex response by the medic. These NTD attempts were made similar to an intravenous insertion. It appears the needle was inserted into the skin and the catheter advanced off the rigid needle into the skin and muscle of the chest wall before it had entered into the pleural space. Instead, the needle and catheter should be inserted to the hub into the chest followed by removal of the needle, leaving the catheter in the pleural space.

Limitations of this report are the small number of cases and the fact that only fatalities are included. We do not know if the success rate in survivors would be different. The small number of cases also makes it difficult to draw a definitive conclusion regarding anterior versus lateral placement. It seems prudent to teach both the anterior and lateral approaches as battlefield conditions may require one approach specifically. Not knowing the circumstances of placement (e.g., who, where, when) makes it difficult to analyze why an attempt was unsuccessful. Certainly, the training and experience of the individual performing the procedure are key. The question of live-tissue training versus simulator or in vitro training could be addressed. Unfortunately, we lack accurate and reliable prehospital care records in most instances. We do not know if these failed insertions were made by medics or combat lifesavers, nor do we know the level or frequency at which the Operators were trained. A reliable casualty care record documenting point of injury care would allow for a determination of who performed the procedure and inform their leadership of a potential training shortcoming.

Conclusion

TPTX as a result of penetrating trauma is encountered more frequently in the military setting. Untreated, TPTX is rapidly fatal. Needle decompression is lifesaving. In this series, NTD from a lateral approach was more successful than that from an anterior approach, although it was used in fewer cases. Several failed NTD attempts that were noted appear to be the result of improper insertion technique. Also, several anterior insertions were medial to the recommended anatomical landmarks, increasing the risk of injury to the mammary arteries, heart, and great vessels. Anatomical variation and the difficulty of accurately determining the correct anatomical landmarks may account for these instances. The lateral approach is an alternative. Poor documentation of prehospital care continues to hamper reviewers from determining the providers' level and circumstances surrounding failed lifesaving interventions.

Disclosures

Institution work should be attributed to Armed Forces Medical Examiner System.

The opinions or assertions presented hereafter are the private views of the authors and should not be construed as official or as reflecting the views of the Department of Defense, its branches, the U.S. Army Medical Research and Material Command or the Armed Forces Medical Examiner System.

This article fits the description of the U.S. Copyright Act of 1976 of a "U.S. Government Work." This article was written as part of our official duties as a government officer(s) or employee(s). Therefore, it cannot be copyrighted.

References

1. McPherson JJ, Feigin DS, Belamy RF. Prevalence of tension pneumothorax in fatally wounded combat casualties. *J Trauma*. 2006;60:573–578.
2. Holcomb JB, McMullen NR, Pearse L, et al. Causes of death in Special Operations Forces in the Global War on Terror. *Ann Surg*. 2007;245:986–991.

3. Harcke HT, Pearse LA, Levy AD, Getz JM, Robinson SR. Chest wall thickness in military personnel: implications for needle thoracentesis in tension pneumothorax. *Milit Med*. 2007;172:1260–1263.
4. United States Army Institute of Surgical Research. Tactical Combat Casualty Care Guidelines. Published 17 September 2012. http://www.usaisr.amedd.army.mil/assets/pdfs/TCCC_Guidelines_120917.pdf.
5. Dickey N, Jenkins D. Needle decompression of tension pneumothorax and cardiopulmonary resuscitation: Tactical Combat Casualty Care Guidelines recommendation. Defense Health Board memorandum 2011-08, 11 October 2011.
6. Harcke HT, Crawley G, Mazuchowski E. Feedback to the field: an assessment of sternal intraosseous (IO) infusion. *J Spec Oper Med*. 2011;11:23–26.
7. Davis DP, Pettit K, Ron CD, et al. The safety and efficacy of prehospital needle and tube thoracostomy by aeromedical personnel. *Prehosp Emerg Care*. 2005;9:191–197.
8. Ball C, Wyrzykowski A, Kirkpatrick A, et al. Thoracic needle decompression for tension pneumothorax: clinical correlation with catheter length. *Can J Surg*. 2010;53:184–188.
9. Inaba K, Branco B, Eckstein M, et al. Optimal positioning for emergent needle thoracostomy: a cadaver-based study. *J Trauma*. 2011;71:1099–1103.
10. Netto FA, Shulman H, Rizoli SB, et al. Are needle decompressions for tension pneumothorax being performed appropriately for appropriate indications? *Am J Emerg Med*. 2008;26:597–602.
11. Ferrie EP, Collum N, McGovern S. The right place in the right space? Awareness of site for needle thoracocentesis. *Emerg Med J*. 2005;22:788–789.
12. Tien HC, Jung V, Rizoli SB, et al. An evaluation of tactical combat casualty care interventions in a combat environment. *J Am Coll Surg*. 2008;207:174–178.
13. Beckett A, Savage E, Pannell D, et al. Needle decompression for tension pneumothorax in Tactical Combat Casualty Care: do catheters placed in the midaxillary line kink more often than those in the midclavicular line? *J Trauma*. 2011;71(5 Suppl 1):S408–S412.

COL (Ret) Harcke, MC, USA is a forensic radiologist for the American Registry of Pathology, which is a contractor in support of the Armed Forces Medical Examiner System. While on active duty, he served as principal forensic radiologist for the Virtual Autopsy initiative at Dover Air Force Base Port Mortuary. He serves as an adjunct professor of radiology at the Uniformed Services University of the Health Sciences. Dr. Harcke is a graduate of West Point and the Pennsylvania State University College of Medicine. He is airborne, Ranger and flight surgeon-qualified and has served in all the Army components as both a line officer and medical officer with two tours in a combat support hospital in Afghanistan. E-mail: howard.harcke@us.army.mil or mstofa@nemours.org.

LTC Mabry, MC, USA, enlisted in the U.S. Army in 1984. Before attending medical school, he served for 11 years as a U.S. Army Ranger and Special Forces Medical Sergeant. He is also a paramedic, a diving medical technician, high-angle rescue instructor, and flight surgeon. He served as the senior search and rescue medic for Task Force Ranger in Mogadishu, Somalia, and as a Special Forces battalion surgeon during Operation Enduring Freedom in Afghanistan. He is a graduate of the U.S. Army Emergency Medicine residency and EMS fellowship in San Antonio, TX, as well as the Army Command and Staff College. He is currently the director of the Military Emergency Medical Services Fellowship program and has written numerous articles and book chapters related to battlefield medical care.

Lt Col Mazuchowski, MC, USAF, is the Director of the Office of the Armed Forces Medical Examiner, Armed Forces Medical Examiner System, Dover AFB, DE, and an assistant professor of pathology at the Uniformed Services University of the Health Sciences. He is a Distinguished Graduate of the USAF ROTC program at the University of Notre Dame and received his doctorate of philosophy in biomechanics from the University of Pennsylvania and doctorate of medicine from the Uniformed Services University of the Health Sciences. He is a co-author of the *Feedback to the Field* communications.