

Med Quiz

Picture This....

CPT Karen T. Guerrero

A 20 year old active duty Soldier complains of a sudden appearance of a nonpruritic generalized eruption one week after having a streptococcal throat infection. Lesions are on the scalp, trunk, proximal extremities, and genitalia. There are no oral, palmer, or plantar lesions noted.

Question 1:

How would you describe the primary lesion?

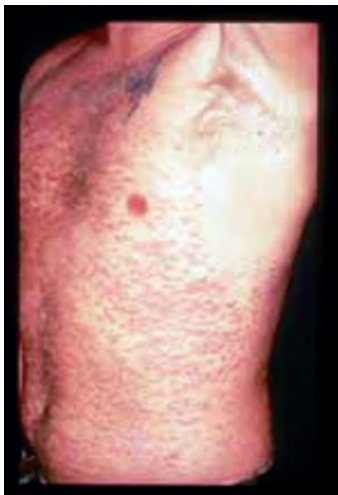

Photo # 1

Question 2:

What is your differential diagnosis?

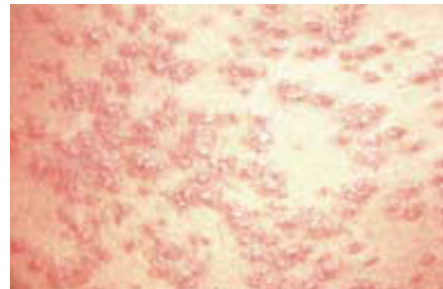


Photo # 2

ANSWERS

Question 1:

Erythematous, well circumscribed papules and plaques with scant fine silvery scale.

Question 2:

Your differential diagnosis for this widespread eruption should include psoriasis, secondary syphilis, pityriasis rosea, and pityriasis lichenoides. A solitary plaque may resemble lichen simplex chronicus. Ill defined lesions such as these on the scalp also include seborrheic dermatitis. The well circumscribed primary lesion with fine silvery hyperkeratotic scale in the distribution noted above is more consistent with guttate psoriasis.

PSORIASIS EPIDEMIOLOGY

Psoriasis occurs in 1% to 3% of the population. The disease has a genetic component likely involving multiple genes with a dominant mode of inheritance and variable penetrance. The disease is lifelong with chronic recurrent exacerbations and remissions precipitated by various environmental, pharmacologic, and psychological stimuli. The extent and the severity of the disease can vary widely. The classic guttate psoriasis presentation occurs during childhood when the first episode is stimulated by streptococcal pharyngitis. Staphylococcus and streptococcal infections were shown to aggravate psoriasis through their toxin production. Streptococcal pyrogenic exotoxin C is a superantigen that has the capacity to stimulate a large number of lymphocytes. Superantigens bypass the normal antigen intracellular processing mechanism and bind directly to major histocompatibility complex molecules leading to an intense and often exaggerated inflammatory cascade. Direct T-cell activation by superantigens may generate a total T-cell population 10 to 100 fold larger than the norm resulting in the release of cytokines that accelerate epidermal proliferation and aid in plaque formation.

The classic psoriasis lesions are distinctive with evolution of erythematous papules to plaques with well-delineated borders and fine, silvery, white adherent scale. Removal of adherent scale will lead to small pinpoint bleeding (Auspitz's sign) which some consider helpful in the diagnosis of psoriasis. Scale can be quite

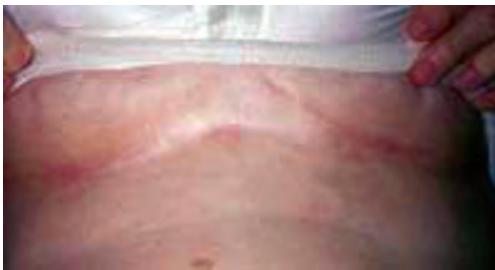


Photo #3

dense on the scalp and the plaque-like nature of the primary lesion can often be obscured. In intertriginous areas like the axilla, groin, inframammary folds, or gluteal crease (photo #3), maceration may lead to decreased or absent scale resulting in slight erythema. This intertriginous presentation is often misleading and results in the misdiagnosis of tinea cruris or erythrasma. The gluteal crease erythema is a strong indicator and helpful in those difficult to differentiate cases. Patients who you feel may have psoriasis should be examined for this prominent, although often unobserved, diagnostic clue.

Psoriasis has a tendency to develop at the sites of physical trauma known as the Koebner phenomenon. Previous surgery sites, sites of previous burns, pinpoint lesions on razor shaven legs or on the face, or the extensor surfaces of the elbows and knees are common sites where the Koebner phenomenon is seen.

CLINICAL VARIANTS

Psoriasis can be considered a spectrum of different cutaneous manifestations with variations in morphology and location of lesions. The different variants of psoriasis may also coexist in a particular individual. Hallmark morphologic features of all primary psoriatic lesions include erythema, thickening, and secondary scale. There can also be considerable overlap with other papulosquamous skin exanthems leading to misdiagnosis specifically with seborrheic dermatitis when the scalp is involved. One subtle sign that favors seborrheic dermatitis is involvement of the external ear canal as well as the scalp. Most scalp psoriatic patients will not have any auricular involvement as noted here (photo #4).

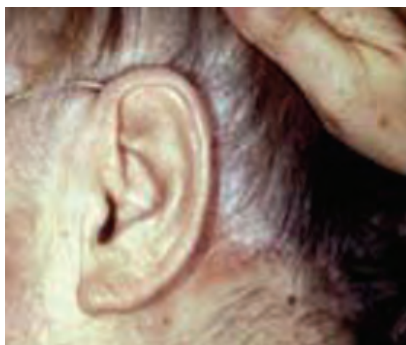

Photo # 4

The most common presentation is chronic plaque-type psoriasis with chronic well-defined plaques usually found on the extensor surfaces. The guttate variant demonstrated in photos one and two represents the most common presentation in a patient before age 20. The distribution is diffuse and primarily affects the trunk and extremities. Lesions are small ranging from two to five millimeters in diameter. In the guttate variant, throat cultures should be taken to rule out streptococcal infection. A high incidence of positive antistreptolysin O titers has been demonstrated in this patient population. Generalized pustular psoriasis is a serious and even rarely fatal disease where patients present in a toxic, febrile state with leukocytosis. In this vari-

ant, erythema begins in flexural areas with migration to other surfaces. Superimposed on the erythematous lesions are tiny sterile pustules that coalesce into the “lakes of pus.” Erythrodermic psoriasis is another severe but uncommon variant of psoriasis with a diffuse extensive erythema and overlying exfoliative laminated scale. Patients often require hospitalization given the extent of involvement and the associated morbidity. Severe complications include sepsis, high output cardiac failure, electrolyte imbalances from insensible losses, and adult respiratory distress syndrome resulting in death have occurred. Generalized pustular and erythrodermic psoriasis more importantly may be iatrogenically induced in psoriatic patients that are inadvertently or empirically given oral steroids to treat a “generalized dermatitis” or “a non-specific maculopapular rash.” The take home point is to **refrain from empirically treating a papulosquamous eruption with oral or injectable steroids for it may be an atypical psoriatic presentation that could be drastically aggravated once the steroids are withdrawn.**

OTHER ASSOCIATIONS WITH PSORIASIS

Nail involvement has been reported in 10 to 78% of patients and can be a helpful adjunctive diagnostic sign in difficult cases (photo #5). The changes depend on the site of involvement. Psoriasis can affect the nail matrix and the nail bed. Findings can include pitting of the nail plate, leukonychia, or a focal loss of transparency in the nail plate, focal oil spots demonstrating the exocytosis of leukocytes beneath the nail plate, and subungual hyperkeratosis and distal onycholysis with gross separation of the nail plate from the nail bed.

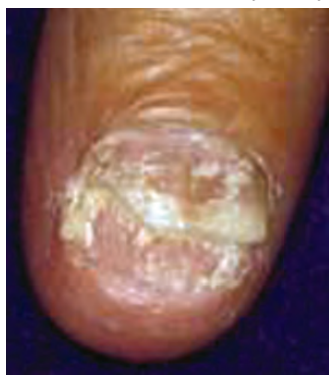

Photo # 5

Psoriatic arthritis may precede, coincide, or follow skin manifestations. Peak occurrence is between ages 20 and 40. The incidence in psoriatic patients is 5 to 30%. The five recognized presentations include asymmetric arthritis, symmetric arthritis, distal interphalangeal joint disease, arthritis mutilans, and ankylosing spondylitis. Treatment should be initiated with either non-steroidal anti-inflammatory agents or disease modifying anti-rheumatic drugs (DMARDs). Non-steroidal anti-inflammatory drugs (NSAIDs) and other physical modalities with physical and occupational therapy can alleviate symptoms associated with mild disease but has no effect on destructive changes. The mechanism of action of NSAIDs is the inhibition of the enzyme cyclooxygenase, which catalyzes the conversion of arachidonic acid to prostaglandins and leukotrienes, both mediators of inflammation. However, NSAIDs may have a potential role in exacerbating skin lesions with increased production of leukotriene B4 and shunting of arachidonic acid metabolites through the lipoxygenase pathway.

DMARDs to include methotrexate, sulfasalazine, or biologically engineered TNF-alpha modulators halt progressive destructive changes. Despite active treatment and coinciding reduction in joint inflammation, psoriatic arthritis may be a progressively deforming arthritis.

PATHOGENESIS

Psoriasis is characterized by hyperproliferation and abnormal differentiation of epidermal keratinocytes, T lymphocyte infiltration, and various endothelial vascular changes in the skin. The proliferation time of psoriatic keratinocytes is more than eight times faster in comparison to normal skin (36 versus 311 days). Daily production of keratinocytes is approximately 28 times greater than the normal epidermis leading to the clinical appearance of

thick plaques. T lymphocytes through the cytokines they release appear to be the principal driver of lesion development and persistence, although endothelial cells, neutrophils, and natural killer T cells may play an adjunctive role. Both T lymphocytes and keratinocytes are stimulated by a cytokine (TGF- β) which leads to an increased production of vascular endothelial growth factor/vascular permeability factor (VEGF/VPF) involved in producing angiogenesis and vascular hyperpermeability. The capillary dilation that results may help nourish the hyperproliferating skin and lead to the characteristic erythematous appearance of psoriatic lesions. Woronoff's ring is a concentric blanching of the erythematous skin at or near the periphery of a healing psoriatic plaque. This is often the first sign that the patient's psoriasis is responding to therapy.

Drugs that can precipitate or exacerbate psoriasis include NSAIDS, lithium, beta blocking agents, calcium channel blockers, captopril, glyburide, granulocyte stimulating factor, interleukins, systemic interferon therapy, lipid lowering agents, terbinafine, and antimalarial agents. Hypocalcemia has been reported to be a triggering factor for generalized pustular psoriasis. Psychogenic stress is also a systemic triggering factor and can be associated with initial presentations or flares of pre-existing disease.

DIAGNOSIS/TREATMENT

Diagnosis is typically made clinically or with identifiable triggers such as prior streptococcal pharyngitis. Biopsy confirmation is recommended for documentations purposes for all service members who do not have obvious psoriasis on a clinical basis. Based on the extent of disease and patient risk factors, treatments can range from topical agents for milder forms to phototherapy or systemic agents for severe psoriasis. The goal of all treatments is to control the disease process and maintain a fully functional, worldwide deployable service member. Many patients do not understand that remission of psoriasis may imply maintenance with a few scattered lesions that respond to intermittent topical therapy. Several of the systemic immunosuppressive medications, systemic retinoids, and immunomodulators have significant adverse effects and toxicities. Risks to benefits of all treatments including topical therapy should dictate therapies and are best applied by the dermatologist or in consultation with them.

Topical treatments currently are the mainstay of psoriasis therapy for most patients with mild to moderate disease. Topical corticosteroids directly modulate many of the cytokines involved in the psoriatic process and may inhibit transcription factors that stimulate cytokine gene transcription. Topical corticosteroids are limited in efficacy if large body surface areas are involved and if lesions themselves are hyperkeratotic preventing adequate absorption of the topicals. A commonly used non-steroidal adjunctive therapy is calcipotriol. This agent binds with vitamin D-selective receptors in various cell types important in the pathogenesis of psoriasis and has been shown to inhibit the hyperproliferation and abnormal differentiation of keratinocytes characteristic of psoriatic lesions.

Management of moderate to severe psoriasis may require systemic agents such as oral retinoids, methotrexate, cyclosporine, and biologically engineered immunomodulators. Methotrexate was the first systemic therapy for patients with moderate to severe psoriasis and is still the most frequently prescribed of these agents. Methotrexate blocks DNA synthesis in rapidly proliferating epidermal cells, inhibits T and B lymphocytes, and disrupts cytokine secretion. Acitretin is the only systemic retinoid marketed for psoriasis in the United States. Patient history and risk stratification must be assessed before starting any systemic medication. One side effect of relevance is that acitretin with the consumption of alcohol is converted to a by-product with a much longer pharmacologic half-life, putting female patients of child bearing age at risk of teratogenicity for several years after stopping the medication. Newer biologic agents have diversified treatment further by targeting the immune or inflammatory pathway that leads to psoriasis. The three biologics that are currently approved by the Food and Drug Administration (FDA) for the treatment of moderate to severe chronic plaque psoriasis are alefacept (LFA3TIP) and efalizumab (anti-CD11a), both of which act via inhibition of T-cell activation, and etanercept, which is a soluble tumor necrosis factor (TNF) receptor antagonist.

The guttate variant as noted in the pictures has been shown to very responsive to narrow band UVB phototherapy with some cases leading to remission of the disease once a therapeutic dose is achieved.

If you are deployed and have concerns about a puzzling skin condition, you can email your clinical photos and a concise morphologic description of the lesion to our Operational Tele dermatology site at derm.consult@us.army.mil or to me directly at Daniel.Schissel@us.army.mil. The lesion you describe just may make its way to the next edition of **Picture This...**

Thanks for all you do.

REFERENCES

1. Weinstein G.D., McCullough J.L., Ross P.A., Cell kinetic basis for pathophysiology of psoriasis. *Journal of Investigative Dermatology* (1985) 85 : pp 579-583. Abstract
2. Detmar M., Brown L.F., Claffey K.P., Yeo K.-T., Kocher O., Jackman R.W., Overexpression of vascular permeability factor/vascular endothelial growth factor and its receptors in psoriasis. *Journal of Experimental Medicine* (1994) 180 : pp 1141-1146.
3. Skov L, Baadgaard O. Bacterial superantigens and inflammatory skin diseases. *Clinical Experimental Dermatology*. 2000;25:56-61.
4. Nagpal S., Lu J., Boehm M.F., Vitamin D analogs: Mechanism of action and therapeutic applications. *Current Medicinal Chemistry* (2001) 8: pp 1661-1679.
5. Papp KA; Guenther L., Boyden B., Larsen FG., Early onset of action and efficacy of a combination of calcipotriene and betamethasone dipropionate in the treatment of psoriasis. *Journal of the American Academy of Dermatology* - 01-JAN-2003; 48(1): 48-54.
6. Krueger G. Psoriasis-recent advances in understanding its pathogenesis and treatment. *Journal of the American Academy of Dermatology* - 01-JUL-2005; 53(Suppl 1): S94-100.
7. James, W.D., Berger T.G., Elston D.M., *Andrews' Diseases of the Skin Clinical Dermatology* (Tenth Edition 2005) p197.



CPT Karen T. Guerrero graduated from the Uniformed Services University of Health Sciences School of Medicine in 2004. She completed her transitional internship at Brooke Army Medical Center at Fort Sam Houston from 2004 to 2005 and is currently completing her dermatology residency at the San Antonio Uniformed Services Health Education Consortium. CPT Guerrero received her bachelor of science degree with honors in biochemistry and molecular biology from the University of California at Santa Cruz in 1997. In the interim years between undergraduate and medical school matriculation, she was involved in biotechnological research that ranged from stem cell research to immunoassay testing.



LTC Daniel Schissel originated "Picture This" for the MED Quiz. He is a 1993 graduate of the Uniformed Service University of the Health Sciences and completed his internship with the family practice department at Fort Bragg in 1994. He then served as the 2/10th Special Forces Group (Airborne) Surgeon and followed on as the 10th SFG(A) Group Surgeon. He completed his residency training in dermatology at the Brooke Army Medical Center in 1999. LTC Schissel is presently station in Heidelberg, Germany as a staff physician and the European Regional Medical Command Dermatology Consultant. He has authored the dermatology section of the new SOF manual, serves on the USSOCOM Medical Curriculum and Examinations Board, and is the U.S. Army Aviation Dermatology Consultant.