Load Carriage–Related Paresthesias (Part 2)

Meralgia Paresthetica

Joseph J. Knapik, ScD; Katy Reynolds, MD; Robin Orr, PhD; Rodney Pope, PhD

ABSTRACT

This is the second of a two-part series addressing symptoms, evaluation, and treatment of load carriage–related paresthesias. Part 1 addressed rucksack palsy and digitalgia paresthetica; here, meralgia paresthetica (MP) is discussed. MP is a mononeuropathy involving the lateral femoral cutaneous nerve (LFCN). MP has been reported in load carriage situations where the LFCN was compressed by rucksack hipbelts, pistol belts, parachute harnesses, and body armor. In the US military, the rate of MP is 6.2 cases/10,000 person-years. Military Servicewomen have higher rates than Servicemen, and rates increase with age, longer load-carriage distance or duration, and higher body mass index. Patients typically present with pain, itching, and paresthesia on the anterolateral aspect of the thigh. There are no motor impairments or muscle weakness, because the LFCN is entirely sensory. Symptoms may be present on standing and/or walking, and may be relieved by adopting other postures. Clinical tests to evaluate MP include the pelvic compression test, the femoral nerve neurodynamic test, and nerve blocks using lidocaine or procaine. In cases where these clinical tests do not confirm the diagnosis, specialized tests might be considered, including somatosensory evoked potentials, sensory nerve conduction studies, high-resolution ultrasound, and magnetic resonance imaging. Treatment should initially be conservative. Options include identifying and removing the compression if it is external, nonsteroidal inflammatory medication, manual therapy, and/or topical treatment with capsaicin cream. Treatments for intractable cases include injection of corticosteroids or local anesthetics, pulsed radiofrequency, electroacupuncture, and surgery. Military medical care providers may see cases of MP, especially if they are involved with units that perform regular operations involving load carriage.

KEYWORDS: *paresthesias, load carriage–related; meralgia paresthetica; mononeuropathy; nerve, lateral femoral cutaneous; Bernhardt–Roth syndrome*

Introduction

Paresthesias are sensations of numbness, burning, and/or tingling, usually experienced as a result of nerve injury or irritation.[1] Several types of compression-related paresthesias have been described in association with load carriage, including brachial plexus palsy, digitalgia paresthetica, and meralgia paresthetica (MP). These are important to understand in the military context because Soldiers who carry heavy loads and wear body armor may present with symptoms indicative of these types of injuries. This is the second of a two-part series addressing symptoms, diagnosis, treatment, and prevention of load carriage–related paresthesias. In Part 1, we addressed rucksack palsy and digitalgia paresthetica; in Part 2, we examine MP in detail.

MP is a neurological disorder involving the lateral femoral cutaneous nerve (LFCN) and is characterized by pain, itching, and paresthesia on the anterolateral aspect of the thigh (Figure 1). The disorder has also been termed Bernhardt–Roth syndrome[2,3] and lateral femoral cutaneous neuralgia.[2–4] Bernhardt–Roth syndrome was named after Martin Bernhardt, who first described the condition, and Vladimir Roth, who later identified the condition in an Army officer wearing a tight belt.[2,3]

Epidemiology

Table 1 lists the prevalence or rates of MP that have been reported in various investigations. The prevalence among

Figure 1 *Area typically affected in MP (shaded).*

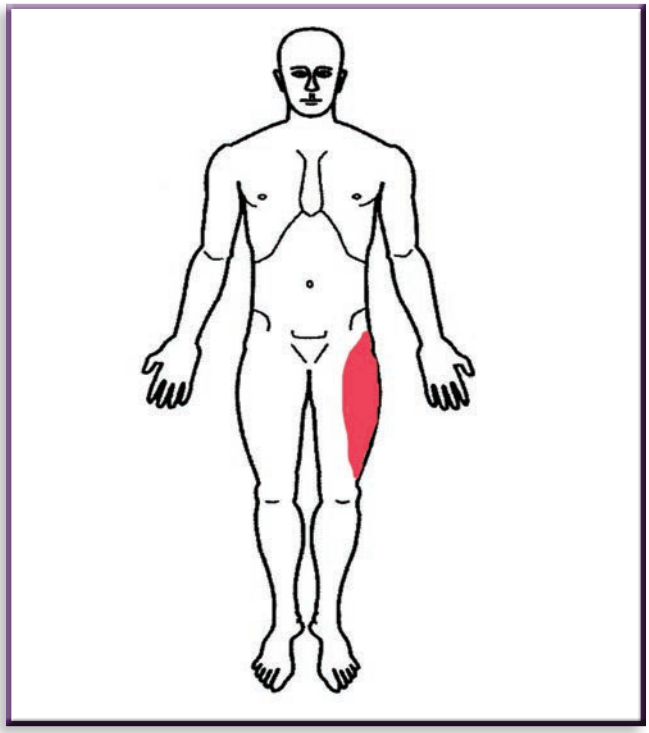

Appalachian Trail hikers[5] was especially high, but the number of study participants was relatively low (n = 280) and cases (n = 10) were deduced from symptoms self-reported by the hikers. The other investigations in Table 1 were diagnosed cases obtained from medical records. Nonetheless, the Appalachian Trail hiker study[5] may suggest that symptoms could be much more prevalent than some studies identify and that many individuals experiencing symptoms do not present for medical care.

We obtained data on MP directly from the Defense Medical Epidemiology Database[6] for all military services (i.e., Army, Navy, Marine Corps, and Air Force). Data were collected on visits to medical care providers that were coded 355.1 (MP) according to the *International Classification of Diseases, Ninth Revision*, and diagnosed from 2006 through 2014. These data are shown in Table 1 (last row) and in Figure 2.

Rates increased during the period examined (Figure 2A). Military Servicewomen had higher rates of MP than military Servicemen (Figure 2B), and rates generally increased with age (Figure 2C). The Army and the Air Force had the highest rates and the Navy and Marine Corps had the lowest (Figure 2D). In general clinical practice, rates increased with age, but, in contrast to the military data, there was little association between MP and sex.[7,8] Other risk factors associated with the disorder include load carriage of longer distance or duration[5] and higher BMI.[7,9]

Etiology

MP is a mononeuropathy caused by a compression of the LFCN, a sensory nerve branch descending from the L-1 to L-3 spinal nerve roots. The nerve innervates cutaneous areas on the lateral thigh, accounting for the sensory deficits reported in this area.[4,10–12] Cadaver studies have shown that the nerve has a wide variety of pathways as it descends from the spine (Figure 3). In the pathways described as types A, B, and C, the LFCN is ensheathed by, or superficial to, the inguinal ligament, and these descending pathways may be most susceptible to compression.[13] A case-control ultrasound study also

Table 1 *Prevalence or Rates of Meralgia Paresthetica in Various Studies*

Study	Participants, Location, Circumstances	Cases, No.	Denominators	Prevalence or Rate
Ecker and Woltman[24]	Diagnosed cases at Mayo Clinic, Rochester, Minnesota	150	Not clear	3.5 cases/ 10,000 people
Boulware[5]	Self-report of symptoms from backpackers hiking ≥7 days on the Appalachian Trail in the eastern United States	10	Hikers	357 cases/ 10,000 people
van Slobbe et al.[8]	Diagnosed cases from computerized files of general practices in Rotterdam, Netherlands, 1990–1998	74	Patient population in Rotterdam	4.3 cases/ 10,000 person-years
Latinovic et al.[47]	Diagnosed cases among 253 medical practices in the United Kingdom, 1992–2000	2,177	Registered patient population in United Kingdom	10.8 cases/ 10,000 person-years*
Parisi et al.[7]	Diagnosed cases in Olmsted County, Minnesota, 1990–1999	262	Olmstead County residents	3.3 cases/ 10,000 person-years†
Defense Medical Epidemiology Database[6]	Diagnosed cases (ICD-9 code 355.1) in the US Military, 2006–2014	3,749	US military population	6.2 visits/ 10,000 person-years

ICD-9, *International Classification of Diseases, Ninth Revision.* *Age-adjusted rate. †Age- and sex-adjusted rate.

Figure 2 *Rates and factors associated with meralgia paresthetica in US military personnel.* **(A)** *Rates from 2006 to 2014.* **(B)** *Association with sex.* **(C)** *Association with age.* **(D)** *Association with military service. AF, Air Force; MC, Marine Corps.*

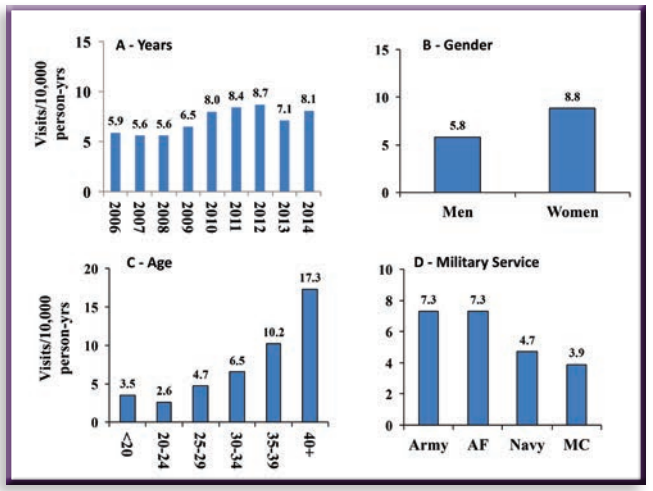

Figure 3 *Anatomical variations of the location of the lateral femoral cutaneous nerve (LFCN) as it exits the abdomen, as described by Aszmann et al.*[13] *in 104 nerves from 52 cadavers. In type A, the LFCN was situated over the top of the iliac crest (4% of cases), the most superficial of all locations; in type B, the LFCN pierced the inguinal ligament (27% of cases); in type C, the nerve sat in the tendon of the sartorius muscle (23% of cases); in type D (26% of cases), the nerve was under the inguinal ligament and medial to the sartorius muscle; in type E (20% of cases), the nerve was medial, on top of the iliopsoas.*

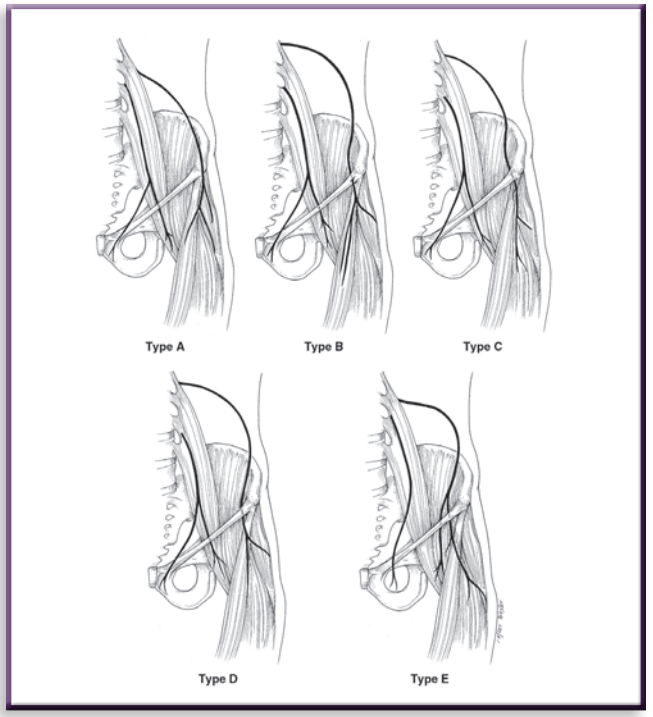

Reprinted with permission from Grossman et al.[13] as adapted with permission from Aszmann OC et al. *Plast Reconstr Surg* 1997;100: 600–604.

showed that close proximity to the anterior superior iliac spine increased the risk of MP.[14]

MP has been reported in load-carriage situations involving rucksack hipbelts,[5] pistol belts,[10,15] parachute harnesses,[3] and body armor.[11,16] Case reports of deployed US and French soldiers found that when soldiers were wearing body armor and were seated in vehicles for long periods, the lower edge of the body armor compressed the inguinal region. This resulted in entrapment of the LFCN, leading to the typical symptoms of MP, including pain and paresthesia.[11,16]

There are a number of other conditions that appear to be associated with MP. Situations that increase abdominal pressure, such as obesity and pregnancy, can cause the disorder.[7,9,17] Compression of the hip area involving trauma from seat belts,[18–20] tight-fitting clothing,[21] limb-length discrepancies,[22] and surgeries[18] have also been reported to cause the disorder. Diabetes mellitus was found associated with MP in one case-control study[7] but not another.[7] Other metabolic conditions like alcoholism and lead poisoning have been postulated to be associated with the disorder, but these have not been proved.[12] Abdominal and pelvic masses should also be considered in the differential diagnosis of MP.[23]

Evaluation

An algorithm for the diagnosis and treatment for MP is shown in Figure 4. Patients with MP typically present with paresthesia in the lateral or anterolateral thigh (Figure 1). Symptoms may be described as numbness, tingling, itching, or a dull ache. There are no motor impairments or muscle weakness, because the LFCN is entirely sensory. As such, deep tendon reflexes (like the patella reflex) should still be present. Symptoms may be present on standing and/or walking, and may be relieved with sitting or adopting other postures unless these posture maintain nerve compression (e.g., they exacerbate pressure from body armor). Palpating the involved area or tapping over the nerve as it exits the pelvis on the inner side of the anterosuperior iliac spine can elicit or heighten symptoms. An area of hair loss may be seen on the lateral or anterolateral thigh from Soldiers rubbing the area. Soldiers should be questioned on trauma to, or compression in, the hip area. A history of diabetes, abdominal or pelvic pathologic conditions, hip arthritis, or previous hip or other orthopedic surgery in that area should be explored.[12,23–25]

Clinical tests to evaluate MP include the pelvic compression test and the femoral nerve neurodynamic test. For the pelvic compression test, the patient lies on the unaffected side. The evaluator uses his or her hand to apply a downward compressive force on the pelvis and holds

Figure 4 *Algorithm for evaluation and treatment of meralgia paresthetica (modified and updated from Grossman et al.[12] and Williams and Trizil[25]). LFCN, lateral femoral cutaneous nerve; NSAID, nonsteroidal anti-inflammatory drug.*

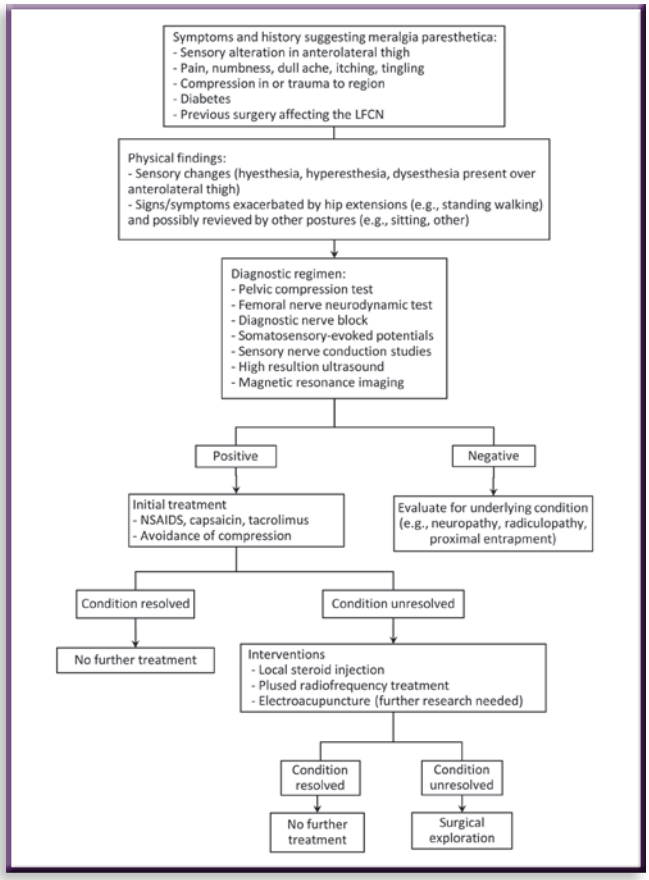

the force for 45 seconds. If symptoms are reduced, the test is positive. The downward pressure presumably relaxes the inguinal ligament and reduces compression on the LFCN, leading to the reduction in symptoms. The pelvic compression test is reported to have a sensitivity (i.e., the ability to detect the disorder) of 95% and specificity (i.e., the ability to identify those without the disorder) of 93%.[26,27]

For the femoral nerve neurodynamic test, the patient lies on the unaffected side, grasps the knee on the unaffected leg to achieve full hip flexion, and flexes their neck toward the knee. The evaluator hooks his or her hand under the calf of the affected leg and grasps the knee with one hand, pushing slightly on the back of the hip with the other hand. The evaluator slowly bends the patient's knee and abducts the hip of the affected leg to place tension on the lateral femoral cutaneous nerve. A positive test is reproduction of the patient's specific MP symptoms rather than just a normal stretch sensation.[26]

Slightly more invasive is a diagnostic nerve block using 5–10mL of 1% lidocaine or procaine. The anesthetics can be injected 1cm medial and inferior to the anterior superior iliac spine or at the point of maximum tenderness. The test is positive if symptoms are quickly relieved and this lasts for 30–40 minutes. It is sometimes useful to retest patients who do not respond 3–4 weeks later.[26,28,29]

Other specialized techniques for the diagnosis of MP may also be useful, especially when the history and physical examination have not been conclusive. These include somatosensory evoked potentials, sensory nerve conduction studies, high-resolution ultrasound, and magnetic resonance imaging (MRI). In one study,[30] somatosensory evoked potentials for MP involving stimulation of the lateral aspect of the distal third of the thigh had a sensitivity of 84% and specificity of 100%, stimulation of the LFCN below the anterior superior iliac spine had a sensitivity of 53% and specificity of 100%, and sensory nerve conduction studies had a sensitivity of 65% and a specificity of 100%. The sensitivity/specificity of high-resolution ultrasound for diagnosis has not been determined, but the technique may useful for comparison of morphological differences of the LFCN on the affected and unaffected sides.[31,32] MRIs read by experienced radiologists had intraobserver reliability of ≥79%, sensitivity of ≥71%, and specificity of ≥94% for the detection of clinically diagnosed MP.[33] MRI or other imaging techniques would also be helpful to investigate a suspected intraabdominal mass compressing the LFCN.[23]

Treatment

The symptoms of MP may be mild and resolve spontaneously or be more severe and limit function.[5,8,26,34] If the symptoms are related to load-carriage issues, the nature of the compression should be identified because symptoms generally resolve with removal of the compression[5,10] (e.g., by changing the configuration of the carried loads or the position of belts). Initial treatment with nonsteroidal anti-inflammatory drugs (NSAIDs) and ice applications (30 minutes three times per day) may assist in relieving pain associated with inflammation of the LFCN.[12,25] Topical treatment with 0.025% capsaicin cream[35] or 0.1% tacrolimus[36] has also shown to be helpful in reducing pain.

A systematic review[37] evaluated the effectiveness of various forms of treatment for MP. The review included observational studies in which there were at least five cases and a follow-up of at least 80% of cases for at least 3 months. One study reported that 18 (62%) of 29 patients recovered completely without intervention. Four studies involving injection of corticosteroids or local anesthetics found recovery or improvement in 130 (83%) of 157 of combined cases. Nine surgical studies involving decompression of the nerve showed benefit in

264 (88%) of 300 cases, and three surgical studies involving neurectomy found benefit in 45 (94%) of 48 combined cases. One case series of 277 patients[25] not reported in the systematic review[37] found that 50% of patients responded well to conservative treatment involving removal of compression, application of ice to the affected area, and NSAID medication. For persistent discomfort, local anesthetic agents and corticosteroids were recommended, but the success of this method was not reported.[25]

In several studies, pulsed radiofrequency treatment was shown successful in relieving pain associated with MP,[38–40] including one involving a female Servicemember.[41] More recently, a case series was reported on 11 patients with intractable MP who were provided pulsed radiofrequency treatment.[42] On the 10-point visual analog pain scale (0cm = no pain, 10cm = worst possible pain), patients rated their pretreatment pain level (mean ± standard deviation) at 6 ± 1. At both posttreatment and at 6 months of follow-up, pain was rated at 1 ± 1. Seven patients were pain free, three had pain relief, and one had a recurrence of pain. This treatment modality provides a nonsurgical alternative for patients with MP who have not responded to other conservative therapies.

Acupuncture was found effective in relieving MP pain in one observational case series involving 10 patients.[43] Two to eight electroacupuncture treatments were associated with a >90% improvement in pain scores in follow-up periods ranging from 2 to 36 months. The mechanism by which acupuncture may be effective is not clear,[44] although some have strongly argued that it may act by blocking neural impulses.[45] One systematic review on acupuncture effectiveness[46] included only conditions involving acupuncture, placebo acupuncture, and no acupuncture studies (N = 13 conditions) and patients with a wide variety of painful conditions. Pain reduction amounted to 4mm on a 100mm visual analog scale (i.e., 4% reduction in pain) in the acupuncture condition compared with the placebo acupuncture, and 10mm (i.e., 10% reduction in pain) in the acupuncture condition compared with the no-acupuncture condition. Thus, acupuncture appears to be another nonsurgical treatment option, but further research on its effectiveness for pain relief in MP is necessary.

Finally, a recent review[26] noted that several case reports have been published that describe relief of MP symptoms in some patients after soft-tissue manipulation or manual therapy applied by a chiropractor or physical therapist. This soft-tissue therapy was designed to improve the mobility of the LFCN through the soft tissues that surround it. However, the research evidence to support this approach is currently weak and further, more rigorous research is required.

Conclusion

Although MP occurs rarely, medical care providers are likely to encounter cases of MP during their careers, especially if they are involved with Soldiers who perform regular operations involving load carriage. MP should be considered when there is pain, itching, paresthesia, and other sensory changes in the anterolateral thigh. Numerous diagnostic tools are available involving joint and muscle mobilization, nerve blocks, somatosensory evoked potentials, sensory nerve conduction studies, high-resolution ultrasound, and MRI.

Initial treatment should be conservative, with removal of the compression and use of NSAIDs and topical capsaicin or tacrolimus. If these are unsuccessful in providing relief, other treatment options, including local steroid injections, pulsed radiofrequency treatment, and surgery, should be considered. Always consider the need for further evaluation for such findings such as intra-abdominal masses, diabetes or other causes of peripheral neuropathic conditions, and hip or other orthopedic pathological disorders, particularly if symptoms do not resolve with nonsurgical treatments. The primary goal should be prevention, but if the condition manifests, the objective will be to reduce pain and restore the LFCN function so that the Soldier can perform as a more effective part of the unit.

Acknowledgment

We thank Ryan Steelman for assistance with the figures and obtaining references.

Disclaimer

The views expressed in this presentation are those of the authors and do not necessarily reflect the official policy of the Department of Defense, Department of the Army, US Army Medical Department or the US Government. The use of trademark names does not imply endorsement by the US Army but is intended only to assist in the identification of a specific product.

Disclosures

The authors have nothing to disclose.

References

1. **National Institutes of Health**. Paresthesia information page. https://www.ninds.nih.gov/Disorders/All-Disorders/Paresthesia-Information-Page. Accessed 14 September 2016.
2. **Pearce JMS.** Meralgia paresthetica (Bernhardt-Roth syndrome). *J Neurol Neurosurg Psychiatry.* 2006;77:84.
3. **Shalev R, Charniles J, Margaliot S.** To the editor. *Aviat Space Environ Med.* 1982;7:290.

4. **Dias-Filho LC, Valenca MM, Guimarães-Filho FAV, et al.** Lateral femoral cutaneous neuraliga: an anatomical insight. *Clin Anat*. 2003;16:309–316.
5. **Boulware DR.** Backpacking-induced paresthesias. *Wilderness Environ Med*. 2003;14:161–166.
6. **Defense Health Agency.** Defense medical epidemiology database. http://www.health.mil/Military-Health-Topics/Health-Readiness/Armed-Forces-Health-Surveillance-Branch/Data-Management-and-Technical-Support/Defense-Medical-Epidemiology-Database. Accessed 15 January 2017.
7. **Parisi TJ, Mandrekar J, Dyck PJB, et al.** Meralgia paresthetica. Relation to obesity, advanced age and diabetes mellitus. *Neurology*. 2011;77:1538–1542.
8. **van Slobbe AM, Bohnen AM, Bernsen RMD, et al.** Incidence rates and determinates in megalgia paresthetica in general practice. *J Neurol*. 2004;251:294–279.
9. **Mondelli M, Rossi C, Romano C.** Body mass index in meralgia parestheica: a case-control study. *Acta Neurol Scand*. 2007;116:118–122.
10. **Erbay H.** Meralgia paresthetica in differential diagnosis of low back pain. *Clin J Pain*. 2002;18:132–135.
11. **Fargo MV, Konitzer LN.** Merlgia paresthetica due to body armor wear in U.S. soldiers serving in Iraq: a case report and review of the literature. *Mil Med*. 2007;172:663–665.
12. **Grossman M, Ducey S, Nadler S, Levy A.** Meralgia paresthetica: diagnosis and treatment *J Am Acad Orthop Surg*. 2001;9: 336–344.
13. **Aszmann OC, Dellon ES, Dellon AL.** Anatomical course of the lateral femoral cutaneous nerve and its susceptibility to compression and injury. *Plast Reconstr Surg*. 1997;100: 600–604.
14. **Moritz T, Prosch H, Berzaczy D, et al.** Common anatomical variation in patients with idiopathic meralgia paresthetica: a high resolution ultrasound case-control study. *Pain Phy*. 2013;16:E287–E293.
15. **Korkmaz N, Ozcakar L.** Meralgia paresthetica in a policeman: the belt or the gun. *Plast Reconstr Surg*. 2004;114:1012–1013.
16. **Derkenne C, Lamblin A, Demaison X, et al.** A heavy protection. *Mil Med*. 2015;12:e1287–e1289.
17. **Skaggs CD, Winchester BA, Vianin M, et al.** A manual therapy and exercise approach to meralgia paresthetica in pregnancy: a case report. *J Chiropractic Med*. 2006;5(3):92–96.
18. **Nahabedian MY, Dellon L.** Meralgia paresthetica. *Ann Plastic Surg*. 1995;35(6):590–594.
19. **Beresford HR.** Meralgia paresthetica after seat belt trauma. *J Trauma*. 1971;11:629–630.
20. **Blake SM, Treble NJ.** Meralgia paresthetica—an addition to 'seatbelt syndrome'. *Ann R Coll Surg Engl*. 2004;86:1–2.
21. **Park JW, Kim DH, Hwang M, et al.** Meralgia paresthetica caused by hip-huggers in a patient with an aberrant course of the lateral femoral cutaneous nerve. *Muscle Nerve*. 2007;35: 678–680.
22. **Goel A.** Meralgia parestheica secondary to limb length discrepancy; case report. *Arch Phy Med Rehabil*. 1999;80: 348–349.
23. **Sarwark JF.** *Essentials of Musculoskeletal Care*. Rosemount, IL: American Academy of Orthopedic Surgeons; 2010.
24. **Ecker AD, Woltman HW.** Maralgia paraesthetica. A report of one hundred and fifty cases. *JAMA*. 1938;110:1650–1652.
25. **Williams PH, Trizil KP.** Management of mergalgia paresthetica. *J Neurosurg*. 1991;74:76–80.
26. **Cheatham SW, Kolber MJ, Salamh PA.** Meralgia parthetica: a review of the literature. *Int J Sports Phy Ther*. 2013;8: 883–893.
27. **Nouraie SA, Anand B, Spink G, et al.** A novel approach to the diagnosis and management of meralgia paresthetica. *Neurosurgery*. 2007;60:696–700.
28. **Haim A, Pritsch T, Ben-Galim P, et al.** Meralgia parasthetica. A retrospective analysis of 79 patients evaluated and treated according to a standard algorithm. *Acta Orthop*. 2006;77: 482–486.
29. **Jones RK.** Meraligia paresthetica as cause of leg discomfort. *Can Med Assoc J*. 1974;111:541–542.
30. **El-Tantawi GAY.** Reliability of sensory nerve-conduction and somatosensory evoked potentials for diagnosis of meralgia paresthetica. *Clin Neurophysiol*. 2009;120:1346–1351.
31. **Suh DH, Kim DH, Park JW, et al.** Sonographic and electrophysiologic findings in patients with meralgia paresthetica. *Clin Neurophysiol*. 2013;124:1460–1464.
32. **Aravindakannan T, Wilder-Smith EP.** High-resolution unltasonography in the assessment of mergalgi paresthetica. *Muscle Nerve*. 2012;45:434–435.
33. **Chhabra A, Grande PD, Soldatos T, et al.** Mergalia paresthetica: 3-Tesla magnetic resonance neurography. *Skeletal Radiol*. 2013;42:803–808.
34. **Rutherfurd WJ.** Meralgia paraesthetica. *Br Med J*. 1916;2: 583–584.
35. **Puig L, Alegre A, deMoragas JM.** Treatment of meralgia paresthetica with topical capsaicin. *Dermatology*. 1995;191: 73–74.
36. **Gronhagen CM, Tey HL.** Meralgia paresthetica successfully treated with topical 0.1% tacolimus: a case report. *Int J Dermatol*. 2016;55:e32–e33.
37. **Nofal K, Alessia N, Wojtek R.** Treatment for meralgia paraesthetica. *Cochrane Database Syst Rev*. 2012;CD004159.
38. **Philip CN, Candido KD, Joseph NJ, et al.** successful treatment of meralgia paresthetica with plused radiofrequency of the lateral femoral cutaneous nerve. *Pain Phy*. 2009;12:881–885.
39. **Dalmau-Carola J.** Treatment of meralgia paresthetica with plused radiofrequency of the lateral femoral cutaneous nerve. *Pain Phy*. 2009;12:1025–1027.
40. **Choi HJ, Choi SK, Kim TS, et al.** Plused radiofrequency neuromodulation treatment on the lateral femoral cutaneous nerve for the treatment of meralgia paresthetica. *J Korean Neurosurg Soc*. 2011;50:151–153.
41. **Fowler IM, Tucker AT, Mendez RJ.** Threatment of meralgia paresthetica with ultrasound guided plused radiofrequency ablation of the lateral femoral cutaneous nerve. *Pain Practice*. 2011;12:394–398.
42. **Lee JJ, Sohn JE, Choi HJ, et al.** Clinical effectieness of plused radiofrequency neuromodulation for intractable meralgia paresthetica. *Pain Phy*. 2016;19:173–179.
43. **Alexander RE.** Clinical effectiveness of electroacupuncture in meralgia paraesthetica: a case series. *Acup Med*. 2013;31: 435–439.
44. **Moffet HH.** How might acupuncture work? A systematic review of physiologic rationales from clinical trials. *BMC Comp Altern Med*. 2006;6:25.
45. **Silberstein M.** Is acupuncture "stimulation" a misnomer. A case for using the term "blockade". *BMC Comp Alter Med*. 2013;13:68.
46. **Madsen MV, Gotzsche PC, Hrobjartsson A.** Acupuncture treatment for pain: systematic review of randomized clinical trials with acupuncture, placebo acupuncture, and no acupuncture groups. *Br Med J*. 2009;338:a3115.
47. **Latinovic R, Gulliford MC, Hughes RAC.** Incidence of common compressive neuropathies in primary care. *J Neurol Neurosurg Psychiatry*. 2006;77:263–265.

MAJ (Ret) Knapik, USA, served in the military as an enlisted wheel-vehicle mechanic and medic before he was commissioned as a Medical Service Corps officer in the US Army. He retired from military service in 1994 and continued active research at the US Army Research Laboratory and epidemiology at the US Army Public Health Center, before retiring from civil service in 2011. He is a fellow of the American College of Sports Medicine, holds the Order of Military Medical Merit, and is an adjunct professor at Uniformed Services University (Bethesda Maryland) and Bond University (Robina, Queensland, Australia). He currently works as a Knowledge Preservation Fellow at the Oak Ridge Institute for Science and Education, Oak Ridge, Tennessee. E-mail: joseph.j.knapik@JSOMonline.org.

COL (Ret) Reynolds, USA, served as a physician in the US Army for 25 years. During that time, she received board certification in Internal Medicine and Sports Medicine. In addition to serving as an internal medicine and sports medicine clinician at military hospitals, she conducted injury epidemiology studies with Combat forces while serving at the US Army Research Institute of Environmental Medicine (Natick, Massachusetts). After retirement in 2002, she served as a team physician for cadet athletes at the US Coast Guard Academy (New London, Connecticut). She served as primary care sports medicine physician at the Naval Hospital and Naval Air Technical Training Center Branch Clinic (Pensacola, Florida) from 2014 to 2016. She is a fellow of the American College of Physicians. She currently serves as a medical and research consultant at the University of West Florida (Pensacola, Florida) for the Military Sports and Operational Training Injuries Research Program in the Exercise Physiology Department.
E-mail: klrtria@gmail.com.

Dr Orr served in the Australian Regular Army for over 23 years as an infantry soldier, physical training instructor, physiotherapist, and human performance officer. Still serving in the reserves, he coleads the Tactical Research Unit at Bond University in Australia, serves as cochair of Tactical Strength and Conditioning Australia and editor of the *Tactical Strength and Conditioning Report* for the National Strength and Conditioning Association. Dr Orr currently supervises and conducts research for various law enforcement agencies, the military and fire and rescue services, as well as providing consultancy and educational services. E-mail: rorr@bond.edu.au.

Dr Pope is currently an associate professor of physiotherapy and coleads the Tactical Research Unit at Bond University in Australia. Dr Pope provided clinical physiotherapy, rehabilitation, and injury prevention services at the Australian Army Recruit Training Centre before establishing and leading the Australian Defence Injury Prevention Program. As part of this work, and more recently in his university roles, Dr Pope has conducted and supervised wide ranging research and consultancy projects on preventing injuries and enhancing performance during physical activity in tactical training and operational contexts. E-mail: rpope@bond.edu.au.

The Special Operations Medical Association's Official Journal

JSOM

JOURNAL *of* SPECIAL OPERATIONS MEDICINE™

Spring 2017
Volume 17, Edition 1

THE JOURNAL FOR OPERATIONAL MEDICINE AND TACTICAL CASUALTY CARE

Inside this Issue:

Dedicated to the Indomitable Spirit and Sacrifices of the SOF Medic

A Peer-Reviewed Journal That Brings Together the Global Interests of Special Operations' First Responders