

Tactical Combat Casualty Care February 2010



**Direct from the Battlefield: TCCC Lessons
Learned in Iraq and Afghanistan**



TCCC Lessons Learned in Iraq and Afghanistan

- Reports from Joint Theater Trauma System (JTTS) weekly Trauma Telecons
 - Every Thursday morning – worldwide telecon to discuss every serious casualty from that week
- Published medical reports
- Feedback from doctors, corpsmen, medics, and PJs



Train ALL Combatants in TCCC

- Potentially preventable deaths averaging about 20% of all fatalities
- Units that train all members in TCCC have drastically reduced this incidence
- **Need to train ALL combatants in TCCC**





Fatal Extremity Hemorrhage

This casualty was wounded by an RPG explosion and sustained a traumatic amputation of the right forearm at the mid-forearm level and a right leg wound. He bled to death from his leg wound despite the placement of three field-expedient tourniquets.

What could have saved him

C.A.T. Tourniquet

TCCC training for all unit members

***Note: Medic killed at onset of action**



Tourniquets

- **Get tourniquets on BEFORE onset of shock**
 - Mortality is very high if casualties already in shock before tourniquet application
- **If bleeding is not controlled and distal pulse not eliminated with first tourniquet – use a second one just proximal to first**
 - Increasing the tourniquet **WIDTH** with a second tourniquet controls bleeding more effectively and reduces complications





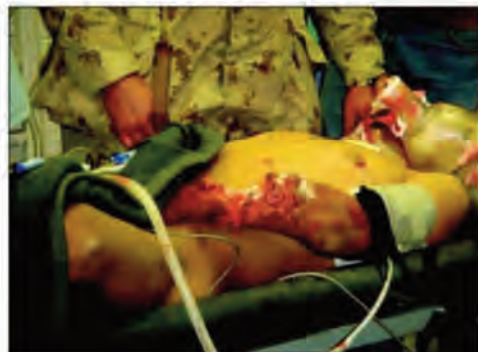Tourniquet Case Report Afghanistan – Nov 2009

- Soldier with gunshot wound to left leg
- Open fracture left femur
- Injury to popliteal artery and vein
- Three CAT tourniquets placed
- Life saved
- Leg doing well
- **2-3 casualties/week being saved with tourniquets**



Tourniquets

- **Tighten velcro band on tourniquets as tight as possible before starting to use windlass – a loose velcro band contributes to tourniquet malfunction**
 - Should be effective with approximately three 180 degree turns of windlass
 - Use second tourniquet as needed






Tourniquets

- **Fake CAT tourniquets that are prone to malfunction are turning up in theater – ensure that you have this NSN tourniquet:**
- **NSN 6515-01-521-7976**

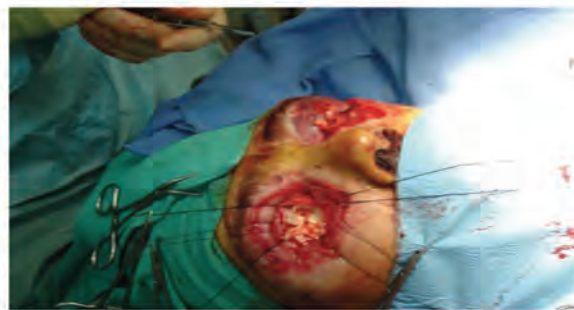


Wear Your Eye Protection!

- **Jan 2010**
- **22 y/o near IED without eye protection**
- **Now blind in both eyes**
- **Don't let this happen to you – see slides below**



With eye pro – eyes OK

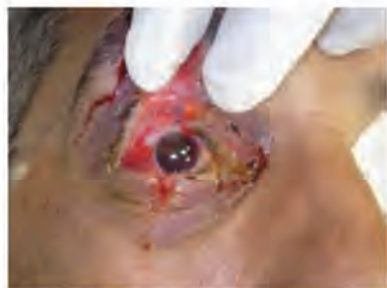

Without eye pro – both eyes being removed

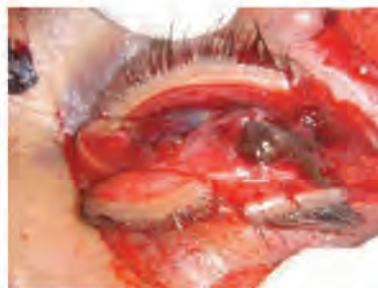

Penetrating Eye Trauma

- **Rigid eye shield for obvious or suspected eye wounds - often not being done – SHIELD AND SHIP!**
- **Not doing this may cause permanent loss of vision – use a shield for any injury in or around the eye**
- **Eye shields not always in IFAKs**



Shield after injury



No shield after injury



Eye Protection



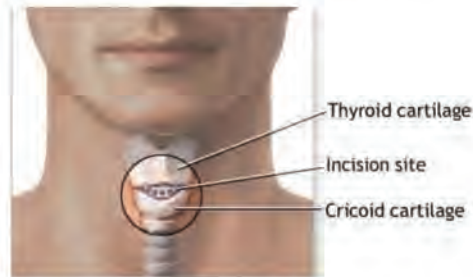
- **Use your tactical eyewear to cover the injured eye if you don't have a shield.**
- **Using tactical eyewear in the field will generally prevent the eye injury from happening in the first place!**



Surgical Airways

Joint Theater Trauma System Email 24 September 09

- 3 field crics done incorrectly in OIF
- One through center of thyroid cartilage and through one of the vocal cords



Surgical Airways: The Rest of the Story


“The setting of the casualty care was at night in a non-permissive environment. The medic had sustained a sacral injury and damaged his NVG's during a hard landing on infil. The casualty had sustained a gunshot wound to the jaw. The medic was not called to the scene for ten minutes due to an ongoing firefight. The jaw was shattered and he had heavy maxillofacial bleeding. The recovery position was attempted repeatedly, but the casualty refused to remain like that. Anxiolysis was attempted with Versed to facilitate maintaining the airway with position alone, but did not work. The casualty became increasingly combative and the decision was made to perform the cric out of fear of completely losing the airway during evacuation. Due to the fact that the medic's NVGs were damaged, an operator (former 18D with two successful prior combat cric's) attempted the procedure with assistance by the medic. By then all landmarks had disappeared due to soft tissue swelling of the neck. Although complications resulted from the procedure, a definitive airway was established under extremely difficult conditions and the casualty lived.”



Surgical Airways

Recommendations:

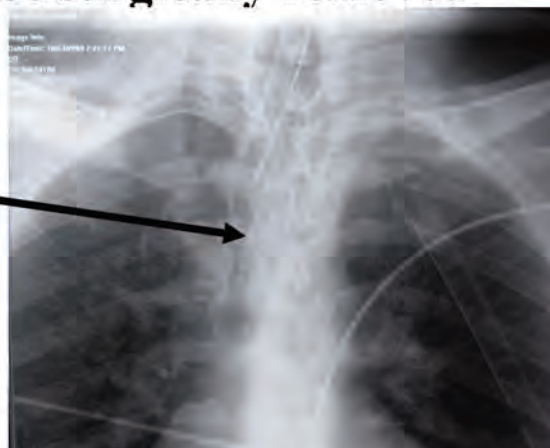- Live tissue training for this procedure if possible
- “Sim Man” trainer may be second-best option
- Don’t attempt surgical airway just because the casualty is unconscious
- **Try the “sit-up and lean forward” position prior to attempting a surgical airway**



Surgical Airways

If you cut the endotracheal Tube, you must tape it very securely or the tube will slip down into the trachea, cease to function correctly, and have to be surgically removed

Like this one.....





IED Casualties

- **IED blast casualties often have multiple mechanisms of injury**
 - Blunt trauma
 - Penetrating trauma
 - Blast
 - Burns
- **Majority of casualties are now from IEDs**



IED Casualties

- **IED casualties – many have spinal fractures, especially thoracic**
- **Try to maintain spinal alignment in blunt trauma casualties**





IED Casualties

- **IED events – be alert for secondary IEDs or ground assaults after initiation of the IED**

