Fracture Detection in a Combat Theater: Four Cases Comparing Ultrasound to Conventional Radiography

William N. Vasios, APA-C; David A. Hubler, 18D; Robert A. Lopez, 18D; Andrew R. Morgan, MD

Abstract

Ultrasound (US) is rapid, non-invasive, simple, effective, and presents a viable and practical alternative to conventional radiography (CR) for the Special Forces Medical Sergeant (18D), particularly in the deployed setting. The authors present four cases that illustrate the ability of US used by the 18D to detect fractures in a combat theater. This success invites a debate as to what extent the Special Operations Forces (SOF) community should field US as it demonstrates a number of distinct advantages over the existing gold standard of portable conventional radiography.

Introduction

Utilizing portable ultrasound for the detection of fractures by the 18D in a combat theater or austere environment is a viable and practical option compared to detection with CR. 1st Battalion, 3rd Special Forces Group (Airborne) SFG(A) recently deployed to Afghanistan in support of Operation Enduring Freedom (OEF). Utilizing the Special Operators Clinical Level Ultrasound (SOLCUS) training outline proposed in the Fall 2008 edition of the JSOM,[1] a total of 29 18Ds received an average of 16.7 hours of US training prior to deploying. Over the course of the deployment, 109 patients were evaluated using nine portable US machines, of those, 39 were musculoskeletal (MSK) presentations. Of these 39, fractures were the most common indication.[2]

Training of SOLCUS focused primarily on a variety of applications that included the Focused Assessment with Sonography in Trauma (FAST), pneumothorax detection, and limited MSK examination. While utilizing US to detect fractures is not a novel idea in a hospital or emergency setting,[3-5] use at the 18D level is unique and recommended in patients with a high clinical suspicion.[6] In comparison to CR, the capability and portability of US make a strong argument for its use in the deployed setting. The following cases demonstrate the portable US's shared capability for fracture detection with CR in the hands of the 18D.

The four case studies presented in this article were selected from among the 39 MSK cases collected in the 3rd SFG (A) experience. In each of the cases, 18Ds collected the US images and in two of the cases they also collected the CR images of fracture sites. US did not necessarily change the outcome or management of these four cases since imposed control measures restricted the 18D from making management altering decisions without at least one of the following: 1) a gold standard test, 2) phone contact with a medical officer, 3) presence of an US-trained medical officer, 4) email of the image for review by an US-trained medical officer, 5) an empiric decision to evacuate for further evaluation independent of test result. These limitations prevented a more comprehensive analysis of the data, to include calculations of sensitivity and specificity.

Though it is not conclusive proof, these four cases demonstrate the 18D's ability to properly employ imaging techniques in an austere environment, correlate the two images, and correctly identify fracture pathology. In addition, the authors hope to demystify US images to other SOF medics by juxtaposing images with more familiar CR images of the identical fracture.

Case 1: Femur Fracture

Forty-one year-old local national (LN) male carried to the firebase clinic by his family in severe pain with swelling of his left thigh following a motor-

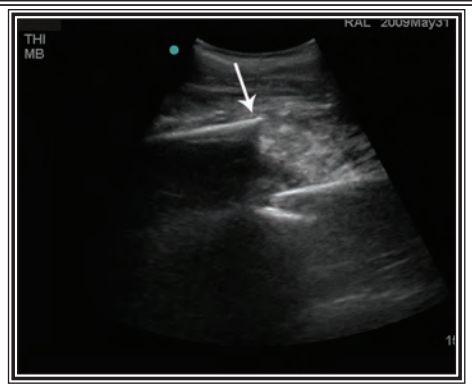

***Image* 1a**

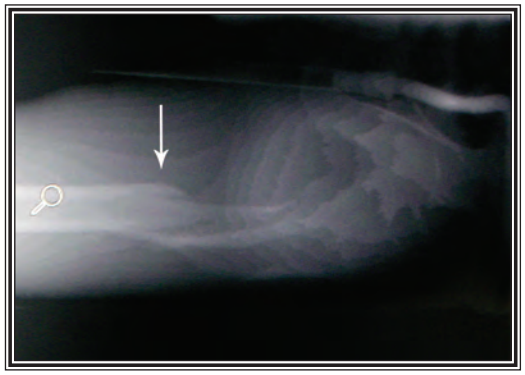

***Image* 1b**

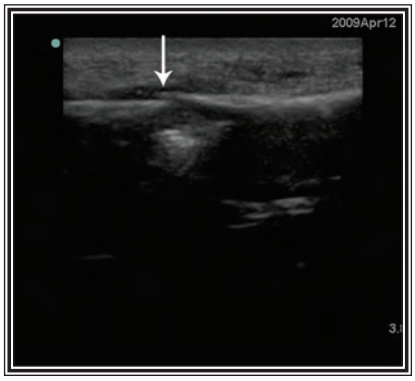

***Image* 2a**

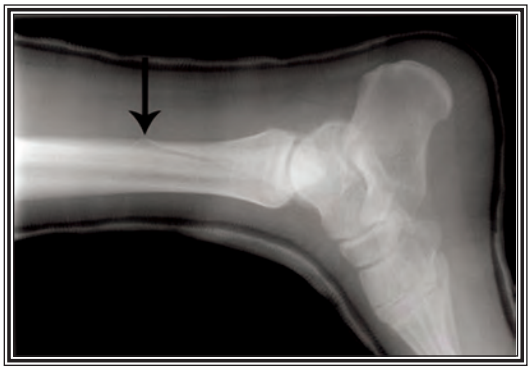

***Image* 2b**

cycle accident. The 18D performed the history and physical (H&P) and suspected a femur fracture. This 18D possessed both US and CR at his firebase clinic. The US confirmed the suspected femur fracture rapidly without further manipulation of the injured patient. (Image 1a) Once the patient's pain was controlled, the 18D used CR for comparison and confirmation. (Image 1b)

Case 2: Distal Fibular Fracture

Thirty-three year-old active duty (AD) male inverted his right ankle while operating an ATV in mountainous terrain. Upon return to the firebase, the visiting group physical therapist and 18D used the portable US to evaluate a suspected distal fibular fracture. (Image 2a) After diagnosing the fracture by US the patient was evacuated to the combat support hospital in Kandahar, where CR confirmed the findings for the orthopedic surgeon. (Image 2b)

Case 3: Phalanx Fracture (Left Index Finger)

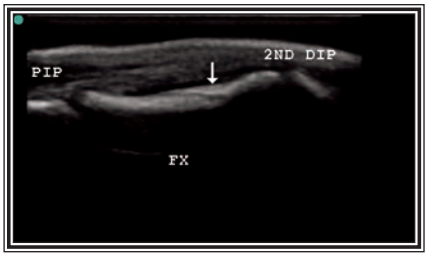

***Image* 3a**

Twenty-one year-old AD male injured his finger while moving equipment pallets. The Soldier presented to BAS for sick call where an 18D performed a H&P. The 18D used US to confirm the suspected fracture. (Image 3a) The patient was sent to the combat support hospital where CR confirmed his fracture. (Image 3b)

***Image* 3b**

Case 4: Tibial Fracture

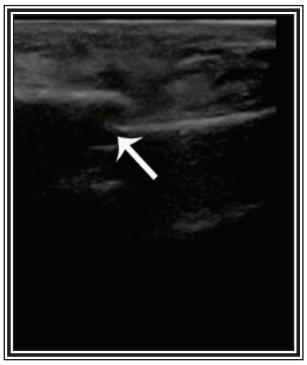

***Image* 4a**

Four year-old LN male presented to firebase clinic carried by his family. The H&P determined the child was a passenger in a motorcycle crash and could not walk or bear weight on his swollen left leg. The 18D used US to confirm a suspected fracture. (Image 4a) Once the pain was controlled the 18D confirmed the fractured tibia with CR. (Image 4b) Both US and CR images where sent to the orthopedic surgeon who accepted the patient transfer via ground transport to a Forward Surgical Team (FST) for repair.

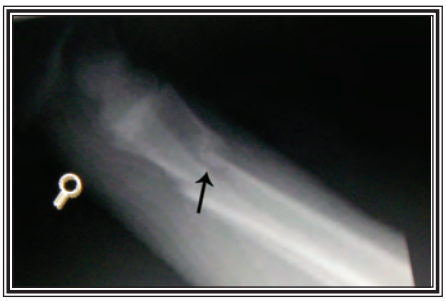

***Image* 4b**

Literature Review

The use of US to detect fractures is well described in medical literature. The traditional obstacles to US use by non-radiologists include: training, sensitivity, specificity, utility, and practicality especially at the non-physician level. These obstacles have been addressed, overcome, and described in recent literature. In an effort to introduce the scientifically validate non-physician capability to learn US, Monti, et al., demonstrated the ability of non-medical personnel to detect pneumothoraces in the porcine model following very brief preparatory instruction. They successfully detected 21 of 22 pneumothoraces with one false negative and 22 of 22 normal hemithoraces.[7] Banel, et al., described the ability of US to detect stress fractures of the metatarsal bones weeks prior to detection by CR.[8] Wong et al., described the utility of US for evaluating the successful reduction of pediatric forearm fractures.[9] Haddad-Zebouni et al., identified the need for an established protocol for limb fracture assessment with US and further describe US features to aid detection.[10] Finally, Dr. John Kendall, the Director of Emergency Ultrasound at the Denver Health Medical Center, Department of Emergency Medicine, Denver, CO, presented "Novel Use of Ultrasound in Trauma" to the Chicago Scientific Assembly, American College of Emergency Physicians in October 2008. His synopsis provided an excellent outline for future areas of training and utilization of US for the 18D.[11]

Discussion

Our community is in the early stages of exploring the role for US in SOF medicine. Musculoskeletal indications are just one of the many potential candidates for inclusion in future curricula. A recent study in SOF literature began exploring the concept of training 18Ds to use US to diagnose fractures. Heiner, et al., demonstrate 100% sensitivity and 90% specificity for 18Ds ability to detect long-bone fractures in a blinded study after a mere three minute block of instruction to the US novice.[12] There is great value in empowering 18Ds to maintain his unit's combat power by minimizing the number of unnecessary evacuations through the appropriate application of US in the austere environment. CR is the traditionally accepted standard in fracture detection in the conventional medical setting; however, US is more practical in the environment that the 18D typically operates due to its increased portability and minimal power requirements.

Current fielding by the U.S. Army Special Forces Command (USASFC) Modified Table of Organization and Equipment (MTOE) authorizes one portable x-ray machine per line battalion headquarters support company. The current USASFC Table of Distribution and Allowance (TDA) Supplement 3 authorizes one portable ultrasound machine per line battalion headquarters support company.[13]

The 18D training course at the USAJFKSWCS at Fort Bragg, NC, dedicates nine hours to radiology training with US "orientation" training totaling less than one hour.[14] Follow on CR training at the Special Forces Group level is virtually non-existent due to proximity to hospital and clinical facilities negating the need to have their one x-ray machine set-up in the battalion aid station. However, US is readily available and utilized for virtually any patient at any time. It provides unlimited opportunities for practical training by the battalion surgeon or physician assistant to the 18D and does not have occupational hazards and regulations associated with radiation.

The portability of US over CR is self-evident. (Figure 1) Portable CR requires a standard pallet and significant coordination of air assets to navigate in theater while portable US can fit into a single hard case the size of a carry-on airline bag or a slightly modified aid bag weighing less than 25 pounds. (Figure 2) In addition to its size and weight, portable US has the power requirements of a modern laptop computer, without the requirement for a generator or electrical infrastructure as with CR. The minimal power requirement of portable US greatly increase its utility in austere and remote applications when compared to CR.

The cost for one portable CR is currently contracted at over $100,000 per machine. A portable US machine ranges from $3,000 for a small PDA-sized, hand-held machine to $40,000 for the laptop sized machine.

Figure 1

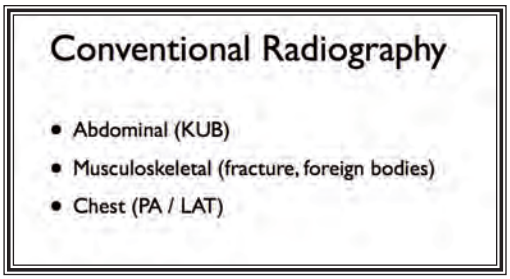

Figure 3a

Figure 2a

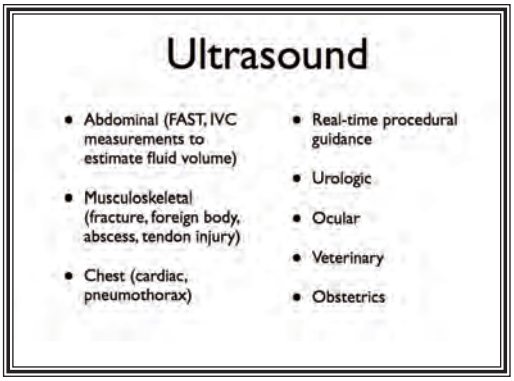

Figure 3b

Figure 2b

Figure 2c

Figure 2d

Figures 3 a&b show the shared capabilities between the CR and US. The staple uses of CR by the 18D are the two-view chest x-ray (CXR), abdomen, and MSK for fractures or foreign bodies. Many complications exist with each of these studies; principally, the overall lack of significant practical experience provided, during initial training and large gaps in exposure to intrinsic CR during deployments. While possible, it is not the norm, or current practice, to have CR at every firebase. Ultrasound voids most of the significant limitations and risks of CR through decreased radiation exposure while obtaining similar clinical information yielded by CR.

Conclusion

The authors acknowledge the target audience of the *Journal of Special Operations Medicine* and the potential influence this article will have on their opinion of SOLCUS and its potential role in SOF medicine. Our recommendations are directed specifically at current and future SOF battalion surgeons, physician assistants, and every 18D worldwide. The boundaries of SOLCUS remain undefined, but early indications strongly support further study within the SOF medical community. The ability to visualize, and record serial images of a patient's injuries is far too valuable to wait for others to pioneer. Utilizing US to detect fractures is only one example of many potential novel applications of US in combat. The authors hope this article inspires you to exploit this technology's fullest potential. Lean forward and seek specialized training as a supervising medical professional – it makes sense and has a place in the 18D armamentarium.

References

1. Keenan S. (2008). Ultrasound in Special Operations Medicine: A proposal for application and training. *JSOM*, Vol. 8, Ed. 4: 47-54.

2. Morgan, A. R., (2010). Special Operator level clinical ultrasound: An experience in application and training. *JSOM*, 10(2); Spring: 16-21. (This edition)
3. Banal, F., (2009). Sensitivity and specificity of ultrasonography in early diagnosis of metatarsal bone stress fractures: A pilot study of 37 patients. *Ann Rheum Dis*, Abstract.
4. Weiss, D., (2005). The use of ultrasound in evaluating orthopaedic trauma patients. *J Am Acad Orthop Surg*, Vol. 13, No 8: 525-533.
5. Kirkpatrick, A., (2003). Rapid diagnosis of an ulnar fracture with portable hand-held ultrasound. *Mil Med*, Apr; 168(4):312-3.
6. Hunter, J., (2010). Fibular fracture: Detection with high resolution diagnostic ultrasound. *Emergency Medicine Casebook*, p. 118.
7. Monti, J., (2009). Ultrasound detection of pneumothorax with minimally trained sonographers: A preliminary study. *JSOM*, 9(1); Winter: 43-46.
8. Banal, F., (2006). Ultrasound ability in early diagnosis of stress fracture of metatarsal bone. *Ann Rheum Dis*, 65: 977-978.
9. Wong, C., (2008). Ultrasound as an aid for reduction of paediatric forearm fractures. *Int J Emerg Med*, 1: 267-271.
10. Haddad-Zebouni, S., (2008). Limb fractures: Ultrasound imaging features. *J Radiol*, 89:557-563.
11. Kendall, J., (2008). Novel use of ultrasound in trauma. *Chicago Scientific Assembly: American College of Emergency Physicians.*, presented October 27th.
12. Heiner, J. (2010). The ultrasound detection of simulated long bone fractures by U.S. Army Special Forces medics. *JSOM*, 10(2); Spring: 7-10.(This edition)
13. United States Army Special Forces Command Table of Distribution and Allowance, Supplement 3.
14. Special Forces Medical Sergeant course Program of Instruction, 18 Oct 2009.

CPT William Vasios, APA-C, is the outgoing Battalion Physician Assistant for 1st Battalion, 3rd Special Forces Group (Airborne) and the incoming Physician Assistant of the United States Army Special Forces Command (Airborne) in Fort Bragg, NC. He graduated the Special Forces Medical Sergeants course in 1995 and the Wake Forest School of Medicine physician assistant program in 2002. Over 20 of his 25 years of service are in the SOF Community.

SFC(P) David Hubler is the NCOIC and Senior Special Forces Medical Sergeant for 1st Battalion, 3rd Special Forces Group (Airborne) in Fort Bragg, NC. SFC(P) Hubler served five years as a medic on an operational detachment prior to becoming the Battalion Medical NCOIC for the past two years. He has five Operation Enduring Freedom deployments.

SFC Robert Lopez has been a Detachment Special Forces Medical Sergeant in 1st Battalion, 3rd Special Forces Group (Airborne) in Fort Bragg, NC for the past three years. SFC Lopez is currently on his second Operation Enduring Freedom deployment to Afghanistan and has one prior Operation Iraqi Freedom deployment.

MAJ Andrew Morgan, MC, is the Battalion Surgeon for 1st Battalion, 3rd Special Forces Group (Airborne) in Fort Bragg, NC. Prior to his assignment to 3rd SFG(A) he served in joint overseas assignments with various SOF units while practicing as a staff emergency physician at Womack Army Medical Center, Fort Bragg, NC. He is a 2002 graduate of the Uniformed Services University of the Health Sciences and a 2005 graduate of the Madigan AMC-University of Washington Emergency Medicine Residency.