

SPONTANEOUS PNEUMOPERICARDIUM, PNEUMOMEDIASTINUM, AND SUBCUTANEOUS EMPHYSEMA IN A 22-YEAR OLD ACTIVE DUTY SOLDIER

David Thompson, MPAS, PA-C

USASOC Sustainment Brigade and Womack Army Medical Center, Department of Emergency Medicine

ABSTRACT

A radiological case study of spontaneous pneumopericardium, pneumomediastinum, and subcutaneous emphysema is reported in a 22-year old active duty male Soldier undergoing survival, evasion, resistance, and escape (SERE) training and presenting for evaluation of sore throat and retrosternal chest pain. The patient is one of several that presented with similar symptoms in a 24-hour period. After close observation, he was released to his unit and recovered well.

Key Words: pneumopericardium, pneumomediastinum, subcutaneous emphysema, SERE

BACKGROUND

Pneumomediastinum (PM) was first described by Laennec in 1819 as a consequence of traumatic injury. Spontaneous pneumomediastinum (SPM) was reported in 1939 by Hamman, for whom the Hamman sign is named. Pneumomediastinum is defined as free air or gas contained within the mediastinum, which almost invariably originates from the alveolar space or the conducting airways. The etiology of PM is multifactorial. Many authors distinguish SPM as a form of PM that is not associated with blunt force or penetrating chest trauma, endobronchial or esophageal procedures, neonatal lung disease, mechanical ventilation, chest surgery, or other invasive procedures.¹

PM rarely leads to clinically significant complications. More commonly, the associated or precipitating condition underlying PM may be the cause of significant illness. On rare occasions, tension PM has been reported in which elevated mediastinal pressure leads to diminished cardiac output because of direct cardiac compression or reduced venous return. When extensive subcutaneous and mediastinal gas is present, airway compression may also occur.

The generally accepted explanation for the development of PM is that following alveolar rupture, gas can dissect along the perivascular sheath into the mediastinum to produce pneumomediastinum. Symptoms of pneumomediastinum include a sensation of fullness in the chest, pleuritic chest pain that may radiate to the shoulders, dyspnea, coughing, hoarseness, and dyspha-

gia. Crepitation in the neck due to associated subcutaneous emphysema may be present, and a crackling sound heard over the heart during systole (Hamman's sign) may be appreciated upon auscultation.²

The dissection of free air may not be confined solely to the mediastinum. Zylak et al. note that the mediastinum communicates with the submandibular space, the retropharyngeal space, and vascular sheaths within the neck.³ In addition, two routes of communication with the retroperitoneum have been noted: via a tissue plane extending through the sternocostal attachment to the diaphragm, as well as periaortic and periesophageal fascial planes. As a result, air present within the mediastinum may dissect through these tissue planes, causing pneumopericardium, pneumothorax, subcutaneous emphysema, pneumoperitoneum, or pneumoretroperitoneum.⁴

Pneumomediastinum is a relatively rare condition. PM has been described in the literature as a complication of a scuba diving related injury. A single case was described by Holmes in *Military Medicine* in 1999 about a Soldier who developed PM after exposure to high concentration smoke.⁵ Grossman described 10 student aviators in the Israeli Air Force who experienced a single, uncomplicated episode of PM unassociated with flying.⁶

CASE REPORT

A 22-year old white male presented to the emergency department after transport by front line ambulance

from the troop medical clinic (TMC) at an outlying clinic to rule out pneumothorax. He was complaining of a sore throat, neck pain, and shortness of breath with exertion. He denied chest pain. Noted by the triage nurse was subcutaneous emphysema to the anterior neck. The patient had symptoms for two days after prolonged screaming and being slapped in the face during training at the SERE (survival, escape, resistance, and evasion) course. The patient also reported slight retrosternal chest pain, essentially resolved after his transport to the ER. Past medical and surgical history, family medical history, and social history were all unremarkable as was his review of symptoms.

Physical examination revealed a well developed, well nourished white male Soldier in no acute distress, sitting upright on the ER gurney. His vital signs were: temperature 97.8, pulse 73, respiratory rate 16, blood pressure 116/72, and oxygen saturation 97% on room air, 100% on three liters of oxygen. The patient exhibited a normal head, eyes, ears, nose, and throat exam, with easily palpable subcutaneous emphysema on the anterior neck and upper chest. His breath sounds were clear to auscultation bilaterally. His cardiac examination revealed a regular rate and rhythm, but had an easily heard crackling sound with systole best heard at the lower left sternal border. The remainder of his examination was entirely within normal limits.

A posterior, anterior, and lateral chest radiograph and soft tissue neck films were ordered. (See Figure 1 - 3) Tracking of subcutaneous air was easily seen on the soft tissue neck. There was also evidence of pneumopericardium and pneumomediastinum on the chest radiograph. There was no evidence of pneumothorax or pneumoperitoneum.

The patient was observed for several hours in the emergency department. He had a stable ER course without change in condition. His case was discussed with the referring physician assistant and he was discharged to his unit with a “no flying” profile for two weeks and scheduled follow up at his TMC.

DISCUSSION

Spontaneous pneumomediastinum is an uncommon finding in clinical practice. It is often associated with pneumopericardium and subcutaneous emphysema. It can be associated with complications of pneumothorax (1 to 25% mortality rate after treatment if associated with COPD or AIDS) as well as boerhaave syndrome (esophageal rupture following vomiting; mortality rate as high as 50 to 70%).^{7,8} Other predisposing conditions associated with high mortality

rates include trauma (blunt and penetrating, especially high velocity injury), asthma, and tracheobronchial perforation. Typically, without any complications, PM has a low mortality rate.

The diagnosis of PM can be confirmed on the basis of chest and neck radiographs. Typically, a radiolucent band is seen along the cardiac border on the posteroanterior film and retrosternally on the lateral view. No specific treatment is required, but inhalation of 100% oxygen is recommended to hasten resorption of extraalveolar gas. Rarely, mediastinotomy may be required to relieve a tension pneumomediastinum.^{9,10}

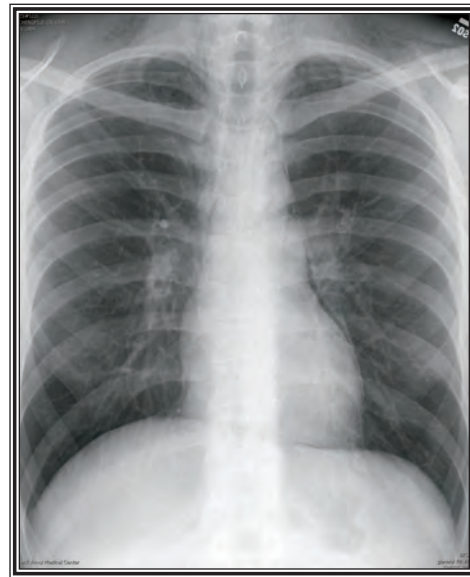


Figure 1

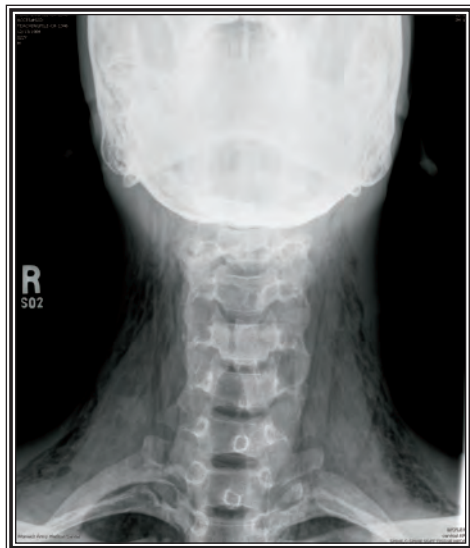

Figure 2

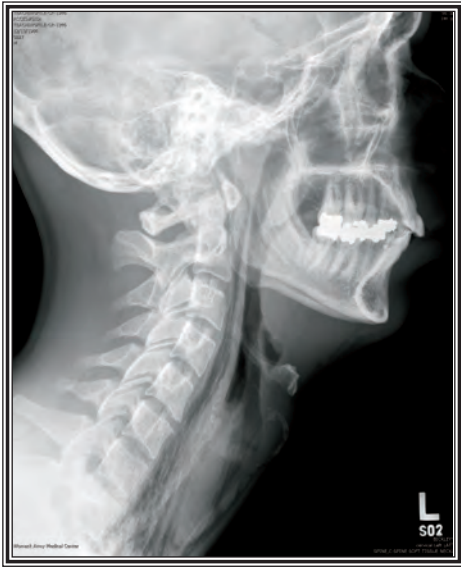

Figure 3

REFERENCES

1. Keith D. Holmes, W. Frederick McGuirt, (1990). Spontaneous pneumomediastinum: Evaluation and treatment *Journal of Family Practice*; 4(422): 425-429.
2. Dipak, Chandy, et al. (2008). Complications of scuba diving, Retrieved from <http://uptodateonline.com>, February, 2008.
3. Zylak, Christopher, et al. (1998). Pneumomediastinum Revisited, Department of Radiology, University of Arizona. Presented as a scientific exhibit at the 1998 RSNA scientific assembly.
4. Patrick L Carolan. (2006). Pneumomediastinum, Retrieved July 2006 from <http://www.emedicine.com/ped/TOPICTopic1832.HTM>.
5. Holmes, PS. (1999). Pneumomediastinum associated with inhalation of white smoke, *Mil Med*; 164(10):751-2.
6. Grossman, A, et al., (2005). Pneumomediastinum in student aviators: 10 cases with return to flying duty. *Aviat Space Environ Med*; 76(1):63-5.
7. Gopalan and Cooke. (2001). Boerhaave's Syndrome, *New England Journal of Medicine*; 344:138-139.
8. Praveen K Roy. (2006). Boerhaave Syndrome, Retrieved August 9 from <http://www.emedicine.com/med/topic233.htm>.
9. Felipe Martinez. (2008). Spontaneous pneumomediastinum, *Applied Radiology Online*; 37(4).
10. Edward A Panacek, Andrew J Singer, Bruce W Sherman, Amanda Prescott, William F Rutherford. (1992). Spontaneous pneumomediastinum: Clinical and natural history *Annals of Emergency Medicine*; 21(10): 1222-1227.



Major David Thompson, MPAS, APA-C is a physician assistant in the Department of Emergency Medicine at Womack Army Medical Center. He is a 1997 graduate of the Bowman Gray School of Medicine of Wake Forest University. MAJ Thompson is a Army reservist assigned to the USASOC Sustainment Brigade. He has served with the 11th Special Forces Group, the 82D Airborne Division, 44th Medical Brigade, and the 10th Mountain Division. His operational deployments include Operation Uphold Democracy and Operation Enduring Freedom.