



Needle Thoracostomy in the Treatment of a Tension Pneumothorax in Trauma Patients: What Size Needle?

Imme Zengerink, MD; Peter R. Brink, MD, PhD; Kevin B. Laupland, MD, MSc, FRCPC; Earl L. Raber, MD, FRCPC; Dave Zygun, MD, MSc, FRCPC; and John B. Kortbeek, MD, FRCSC, FACS

Previously published in *The Journal of Trauma Injury, Infection, and Critical Care*. 2008;64:111–114. Permission granted by Lippincott Williams & Wilkins to republish in JSOM.

ABSTRACT

Background: A tension pneumothorax requires immediate decompression using a needle thoracostomy. According to advanced trauma life support guidelines this procedure is performed in the second intercostal space (ICS) in the midclavicular line (MCL), using a 4.5cm (2-inch) catheter (5cm needle). Previous studies have shown a failure rate of up to 40% using this technique. Case reports have suggested that this high failure rate could be because of insufficient length of the needle. **Objectives:** To analyze the average chest wall thickness (CWT) at the second ICS in the MCL in a trauma population and to evaluate the length of the needle used in needle thoracostomy for emergency decompression of tension pneumothoraces. **Methods:** Retrospective review of major trauma admissions (Injury Severity Score >12) at the Foothills Medical Centre in Calgary, Canada, who underwent a computed tomography chest scan admitted in the period from October 2001 until March 2004. Subgroup analysis on men and women, <40 years of age and >40 years of age was defined a priori. CWT was measured to the nearest 0.01cm at the second ICS in the MCL. **Results:** The mean CWT in the 604 male patients and 170 female patients studied averaged 3.50cm at the left second ICS MCL and 3.51cm on the right. The mean CWT was significantly higher for women than men ($p < 0.0001$). About 9.9% to 19.3% of the men had a CWT >4.5 cm and 24.1% to 35.4% of the women studied. **Conclusions:** A catheter length of 4.5cm may not penetrate the chest wall of a substantial amount (9.9% – 35.4%) of the population, depending on age and gender. This study demonstrates the need for a variable needle length for relief of a tension pneumothorax in certain population groups to improve effectiveness of needle thoracostomy.

A tension pneumothorax (TPT) is a life-threatening condition that is caused by a laceration of the lung. A flap valve effect may develop that allows air to enter the pleural cavity during inspiration but does not permit it to escape during expiration.^{1,2} A technique for emergent chest decompression is needle thoracostomy (NT). NT can be a life-saving technique that releases the pressure inside the thoracic space allowing time to properly insert a thoracostomy tube. NT is frequently used to diagnose a TPT by the rush of air after insertion and converts the existing TPT to a normal pneumothorax.³ In this procedure, a large caliber needle is inserted in the second intercostal space (ICS) in the midclavicular line (MCL) of the affected hemithorax, as recommended by the advanced trauma life support guidelines.⁴ The needle portion is removed, and the plastic sheath is left in place.⁵ The largest caliber needle typically used for this purpose is the 14-gauge 5cm needle with a sheath length of 4.5cm (2 inch).

Previous studies show a failure rate in the pre-hospital environment of as high as 40%.^{6,7} Numerous case reports have been published during the last years, suggesting that the failure rate might be caused by an insufficient length of the cannula used in NT.^{3,8–12}

In a study by Britten et al.,¹³ the chest wall thickness (CWT) was measured by ultrasound on patients scheduled for abdominal ultrasound. Only 4% were found to have a CWT >4.5 cm. Other studies have measured the CWT on computed tomography (CT) scans in small convenience samples of trauma patients and found that 25% to 33% of all patients have a CWT of ≥ 5 cm.^{14,15}

The true CWT at the second ICS MCL is poorly defined and may have important therapeutic implications.

OBJECTIVE

The primary objective is to analyze the average CWT at the second ICS in the MCL in a trauma population. The second is to evaluate the length of the needle

used in NT for emergency decompression of tension pneumothoraces.

METHODS

This study is a retrospective review of chest CT scans performed on trauma patients at the Foothills Medical Centre in Calgary, Canada. For this study, approval from the Conjoint Health Research Ethics Board was granted. The Foothills Medical Centre is the sole tertiary trauma center serving Southern Alberta with a referral population of approximately 1.75 million.

Radiographic records of all major trauma patients (Injury Severity Score [ISS] >12) and age ≥ 18 who were admitted in the period from October 24, 2001 until March 31, 2004 were reviewed to identify those who underwent a CT scan of the chest. All of these CT scans were retrieved and reviewed by the principal author. CT scans that did not meet quality criteria of visualization and reproduction or did not image more than half of the clavicles were excluded. The variables measured were age, gender, CWT, and whether the patient was scanned with arms up (routine) or down during the examination.

All of the data were collected by review of the CT scans on the Foothills Medical Centre PACS (Picture Archive and Communication System) on dedicated diagnostic workstations (AGFA, Holland, IMPAX platform V 4.5). Information was collected on a standard data collection Excel-sheet. Demographic information was obtained from the Alberta Trauma Registry.

As per the standard of practice for NT treatment of a TPT, the CWT was measured in the MCL in the second ICS. Accurate measurement of each patient's right and left CWT was calculated by the following method. Review of the coronal scout image (an initial low dose radiograph-like image from which the subsequent CT scan's field of view is planned), allowed for identification of the middle of the clavicle. From this point on the coronal scout image an accurate 3D cross-reference was made to the axial images to subsequently identify the second and third ribs and thus the second ICS. A precise measurement of the CWT was performed using the workstation's caliper measurement tool.

Data were analyzed by using Stata 8.0 (Stata Corp, College Station, TX). Means, standard deviations, and median with interquartile range (IQR) were used to describe normally or skewed variables, respectively. Group means were compared using the Student's *t* test and medians using the Mann-Whitney *U* test. Fisher's exact test was used for comparison of categorical data. A power analysis was performed a priori based on the outcome of the study of Givens et al.,¹⁴ with the result of n

≥ 288 . Subgroup analysis on men and women, <40 years of age and ≥ 40 years of age were defined a priori.

RESULTS

A total of 774 patients, of whom at least one side of their chest wall was measured, were studied; 604 (78%) were men and 170 (22%) were women. The median age was 40 (IQR, 25 – 53) years. The mean ISS was 23, the median was 20.

The mean CWT of female patients was significantly higher than that of the men as shown in Table 1.

Table 1 Mean Chest Wall Thickness (cm) in the Second Intercostal Space Midclavicular Line

	Right	Left
Female	3.84 ± 1.17	3.92 ± 1.42
Male	3.41 ± 1.04	3.37 ± 0.99
<i>p</i> value	<0.0001	<0.0001

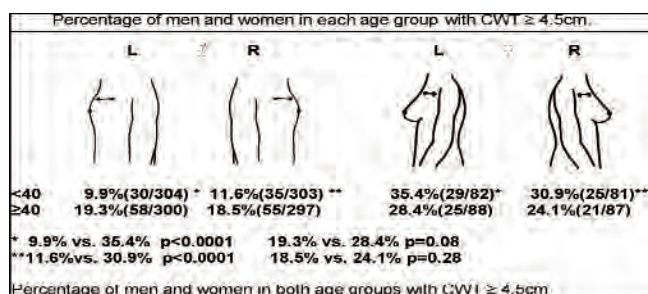


Figure 1. CWT 4.5cm

For male patients, the CWT increased with age (left side, 3.15 – 3.60cm and right side, 3.22 – 3.62cm, $p < 0.0001$). For female patients, the chest wall became thinner with age but the difference was not significant.

In men <40 years, approximately 10% exceeded a CWT of 4.5cm, jumping to 19% for men ≥ 40 years. For women <40 years, the number with a CWT greater than 4.5cm was a third, falling to a fourth for those ≥ 40 years. Figure 1 illustrates the significant difference between the percentages of each gender in the age group under 40, but not in the age group of ≥ 40 years.

The effect of the position of the arms during scanning was particularly noticeable in women. Of the female patients with their arms down 72.2% (left) and 57.1% (right) had a CWT ≥ 4.5 cm versus 28.9% (left) and 23.1% (right) with their arms up (both $p < 0.01$). For male patients with their arms down, these results were 18.9% (left) and 33.3% (right) versus 14.2% (left) and 13.2% (right) when they had their arms up in the scanner ($p < 0.01$ right, $p = 0.41$ left).

Finally, the distance from the anterior wall to the pericardium was measured in each patient. In 19 of 774

patients (2.45%) a 4.5cm needle could potentially penetrate the pericardium when passed through the second ICS MCL. There was no significant difference for age and gender but there was a non-significant tendency toward younger women.

DISCUSSION

An NT is a potentially life-saving emergency procedure in patients with a TPT. It is a simple procedure that allows time for a thoracostomy tube to be inserted using a sterile technique in an adequate setting. If a TPT is not confirmed by a rush of air upon needle placement possible explanations are that a TPT was not present or that the needle did not reach the pleural space.¹⁶ CT images were reviewed to define anatomic depth at the site of NT.

To eliminate beam hardening artifact from degrading the images of the chest on CT, standard protocol is to position patients in the CT scanner with their arms elevated (up) whenever possible. However, in certain circumstances, such as trauma, this is not always possible. We note in this study that the CWT increased for men and women when their arms were left down. For female patients in the supine position with their arms positioned up, breast tissue tends to fall outwards and to the side, resulting in a thinner CWT. In female patients whose arms are left down during the CT scan, breast tissue may not be as spread out and this may result in a significantly higher number of female patients with a CWT >4.5cm. This is a very important practical consideration because while most female patients are scanned in the arms up position, most emergent NTs are performed with the patient's arms in what would be the arms down position.

This study suggests that a 5cm needle with a 4.5cm sheath may fail to decompress a pneumothorax in around 10% of the male patients under 40 years of age and around 19% of the male patients over 40 years of age. For female patients, this risk is even higher with approximately one-third of the women under 40 and one-fourth of the women over 40 years of age having a CWT exceeding 4.5cm. It also shows that men increase their CWT over the years; for women, the effects of age on body habitus may actually reduce CWT at the second ICS. The number of patients whose pneumothoraces might not be decompressed by a 4.5cm needle is potentially even higher given the effect of arm elevation on decreasing CWT during imaging.

Givens et al.,¹⁴ in a similar study in 2004 in Texas, reported a convenience sample of 111 patients. Twenty-two percent of all patients had a CWT over 5cm. The authors did not differentiate in this percentage between male patients and female patients. We found in this considerably larger study, a lower percentage of male patients having a CWT over 4.5cm and a higher percentage of female

patients having a CWT over 4.5cm, even with this lower cut-off point. The IV catheter from BD Insite was used as a reference. The sheath of the needle measures 2.1 X 45mm, the needle itself 50mm. An assumption was made that a CWT of exactly 4.50cm would not be decompressed by a 4.5cm catheter in case of a TPT.

The CWT has been measured in a trauma population to resemble the population in which a TPT is most likely to occur. Givens et al.¹⁴ excluded a woman with a CWT over 10cm because of subcutaneous air; in this study all people with subcutaneous emphysema, anterior hematomas, or other chest wall abnormalities are included.

The patients requiring an NT are more likely to be found in this group.

This study demonstrated that in 2.5% of all trauma patients, a 4.5cm needle used for NT could puncture the heart at the second ICS MCL. This is a potential concern on the left side; interestingly, in one patient it was the case on the right side because of a mediastinal shift.

LIMITATIONS

Although CT may be the most suitable, accurate, and reproducible tool to measure the CWT, there are some limitations with this method, especially in a retrospective review.

The accuracy of where to take the measurement of CWT is critical, as a small error 1cm to either side of the MCL could make a significant difference in the measured CWT because of the acute degree of slope high in the chest cavity at the second ICS in some patients. In addition, when patients in a cervical spine collar are positioned in the CT scanner with their arms up, their subcutaneous soft tissues can be distorted and compressed against the collar. This creates abnormal skin folds that can spuriously increase the measured CWT.

These anatomic and practical limitations could challenge the reproducibility of this studies findings. However, we think that the large sample size makes up for these limitations. Since only one investigator measured all the CT scans with the cut-off point in mind, this could have lead to a bias. Practical application of NT would undoubtedly encompass some variability in site of decompression.

The lack of cadaver verification is a limitation of this study. CT correlation with cadavers has been limited by freezing and preservation that changes soft tissue dimensions.¹⁷ Use of recent CT technology and comparison to fresh cadaver studies demonstrates very high correlation.¹⁸ CT imaging is currently being used for preoperative sizing of implantable medical devices with very good fit at time of surgery or implantation.¹⁹

The study has been performed retrospectively in

only one health center in Canada. This population may not be anatomically representative of other trauma systems with variation in height, build, and body mass index.

CONCLUSIONS

The catheter used in needle decompression of a TPT may not reach the pleural space in 10% to 19% of men and a fourth to a third of women, depending on age. However, several authors,^{3,12,20} do not advise a longer catheter because of the possibility of subclavian or pulmonary artery injury and cardiac tamponade. One author actually did recommend a longer needle if the 14-gauge needle fails.¹⁵

In cases of subcutaneous air or chest wall hematoma, pressure on the catheter may collapse the lumen. To prevent this, the needle can be left in place^{3,10} with use of a stabilization device,²¹ which also creates more length and prevents kinking. But leaving the needle in place can be a danger,¹¹ potentially leading to damage to lung tissue or vital structures. Another suggestion is to use the lateral mid-anterior axillary line (used for chest tubes) for needle decompression,^{2,12,22,23} since there is less fat and muscle tissue and less chance of damage to vessels and heart. However, pleural adhesions are more likely to be encountered and may increase the risk of lung injury when a large pneumothorax is not present.²⁴ Considering the tools available now and their advantages and disadvantages, the 4.5cm needle remains the best choice, but one should be aware of its potential shortcomings.

This study suggests that 4.5cm needles for decompression may be inadequate. Interestingly, no device for needle catheter decompression of TPT has yet been developed to overcome the conflicting challenges posed by variable chest thickness versus the potential risk of damage to lung, heart, and great vessels. These results support performance of a clinical trial to evaluate effectiveness and risk of a longer catheter. Development of a longer introducer needle with a blunt retracting tip may be useful in the clinical setting of suspected TPT.

REFERENCES

1. Dudley H. *Hamilton Bailey's Emergency Surgery*. Bristol: Wright; 1986:231.
2. Leigh-Smith S, Harris T. Tension pneumothorax-time for a re-think? *Emerg Med J*. 2005;22:8–16.
3. Cullinane DC, Morris JA Jr, Bass JG, Rutherford EJ. Needle thoracostomy may not be indicated in the trauma patient. *Injury*. 2001;32:749–752.
4. American College of Surgeons, Committee on Trauma. *Advanced Trauma Life Support Course Manual*. Chicago, IL: ACSCOT; 2004;105:127.
5. Friend KD. Prehospital recognition of tension pneumothorax. *Prehosp Emerg Care*. 2000;4:75–77.
6. Barton ED, Epperson M, Hoyt DB, Fortlage D, Rosen P. Prehospital needle aspiration and tube thoracostomy in trauma victims: A six year experience with aeromedical crews. *J Emerg Med*. 1995;13:155–163.
7. Davis DP, Pettit K, Rom CD, et al. The safety and efficacy of prehospital needle and tube thoracostomy by aeromedical personnel. *Prehosp Emerg Care*. 2005;9:191–197.
8. Heng K, Bystrzycki A, Fitzgerald M, et al. Complications of intercostal catheter insertion using EMST techniques for chest trauma. *ANZ J Surg*. 2004;74:420–423.
9. Britten S, Palmer SH. Chest wall thickness may limit adequate drainage of tension pneumothorax by needle thoracocentesis. *J Accid Emerg Med*. 1996;13:426–427.
10. Pattison GT. Needle thoracocentesis in tension pneumothorax: In sufficient cannula length and potential failure. *Injury*. 1996;27:758.
11. Jones R, Hollingsworth J. Tension pneumothoraces not responding to needle thoracocentesis. *Emerg Med J*. 2002;19:176–177.
12. Jenkins C, Sudheer PS. Needle thoracocentesis fails to diagnose a large pneumothorax. *Anaesthesia*. 2000;55:925–926.
13. Britten S, Palmer SH, Snow TM. Needle thoracocentesis in tension pneumothorax: Insufficient cannula length and potential failure. *Injury*. 1996;27:321–322.
14. Givens ML, Ayotte K, Manifold C. Needle thoracostomy: Implications of computed tomography chest wall thickness [see comment]. *Acad Emerg Med*. 2004;11:211–213.
15. Marinaro J, Kenny CV, Smith SR, et al. Needle thoracostomy in trauma patients: What catheter length is adequate? *Acad Emerg Med*. 2003;10:495.
16. Mines D, Abbuhl S. Needle thoracostomy fails to detect a fatal tension pneumothorax. *Ann Emerg Med*. 1993;22:863–866.
17. Janssens V, Thys P, Clarys JP, et al. Post-mortem limitations of body composition analysis by computed tomography. *Ergonomics*. 1994;37:207–216.
18. Mitsiopoulos N, Baumgartner RN, Heymsfield SB, et al. Cadaver validation of skeletal muscle measurement by magnetic resonance imaging and computerized tomography. *J Appl Physiol*. 1998;85:115–122.
19. Warriner RK, Haddad M, Hendry PJ, Mussivand T. Virtual anatomical three-dimensional fit trial for intra-thoracically implanted medical devices. *ASAIO J*. 2004;50:354–359.
20. Butler KL, Best IM, Weaver WL, Bumpers HL. Pulmonary artery injury and cardiac tamponade after needle decompression of a suspected tension pneumothorax. *J Trauma*. 2003;54:610–611.
21. Allison K, Porter KM, Mason AM. Use of the Asherman chest seal as a stabilization device for needle thoracostomy. *Emerg Med J*. 2002;19:590–591.
22. Biffi WL. Needle thoracostomy: A cautionary note [comment]. *Acad Emerg Med*. 2004;11:795–796.
23. Rawlins R, Brown KM, Carr CS, Cameron CR. Life threatening hemorrhage after anterior needle aspiration of pneumothoraces. A role for lateral needle aspiration in emergency decompression of spontaneous pneumothorax. [comment]. *Emerg Med J*. 2003;20:383–384.
24. Goodman LR, Putman CE, eds. *Intensive Care Radiology, Imaging of the Critically Ill*. Philadelphia: W.B. Saunders; 1982:99–100.