

A Novel Application of Hydrogel to Improve the Asherman Chest Seal® in a Deployed Environment

Farzad Nowrouzadeh, MD

ABSTRACT

There are many challenges when practicing medicine in an operational environment. These challenges can be compounded with multiple traumatic injuries and extreme environments. The Asherman chest seal® has been issued to the U.S. Navy as a standard piece of medical equipment used to treat thoracic injuries. In the austere setting, there have been a number of case reports of the device failing to maintain a seal. By using an adhesive material called hydrogel, a water based polymer compound, with the chest seal, successful seal of penetrating chest wounds have been reported. This combination provides a way to improve the effectiveness and efficiency of medical personnel's live-saving gear.

Introduction

All SOF Corpsmen, Medics, PJs, and medical officers have to face challenges and adapt to their environment while providing optimal care for their Soldiers, Sailors, Marines, and Airmen in an operational theatre. One of the challenges faced in Operation Iraqi Freedom (OIF) is overcoming obstacles to bandaging and wound care in temperatures regularly greater than 100°F. This condition makes the patient, with long sleeve uniform and body armor, prone to perspiration. One problem medical personnel face is with the Asherman chest seal®, a standard piece of equipment for battalion aid stations

(BAS), used for the treatment of penetrating chest injury and pneumothorax. In an open pneumothorax, there is free communication through a chest wall wound between the pleural space and the atmosphere. Entry of air with each respiratory cycle results in progressive collapse of the ipsilateral lung. The larger the defect in the chest wall, the greater is the rate at which pleural air accumulates, and the more rapid is the collapse of the ipsilateral lung.¹ This pathophysiology is similar to that in tension pneumothorax because collapse of the lung and shift of the mediastinum to the opposite side will cause hypoxemia and decreased venous return. The traditional chest seal is an occlusive dressing intended to treat an open pneumothorax and preventing tension pneumothorax in chest injuries from gunshots, stab wounds, or other penetrating chest trauma (see Figure 1). On the Asherman chest seal®, the rubber one-way valve is located in the center and is designed to theoretically let air and blood escape while preventing re-entry of either. The seal is applied to the wound, and held there by a thin adhesive. With dry, clean skin, the chest seal maintains its adhesion.

On several reported occasions; however, the device did not maintain its seal when applied to bloody and, (many times) sweat-drenched skin, hair, and tissue, despite the use of gauze to dry the wound prior to application. In an operational environment where medical officers at Level 1 aid stations not only see poly-trauma to individual casualties, but multiple casualties simultaneously, it is pivotal to have equipment that can be relied upon to function properly. This point is even more stressed, as the medical evac-

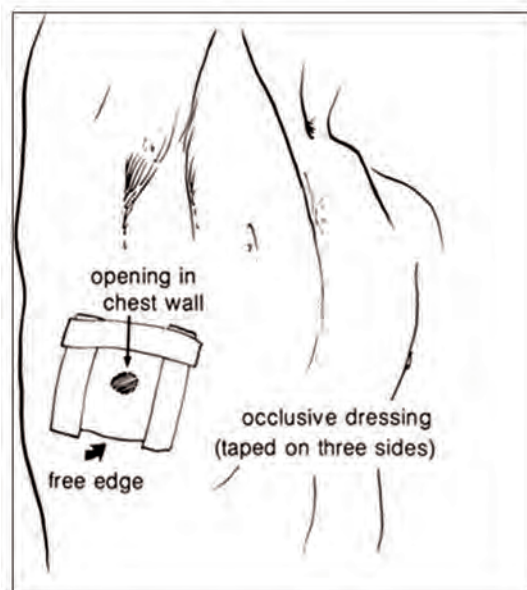


Figure 1

uation tempo has quickened, where patients are at Level 1 or Level 2 facilities for a few hours at most, and then transferred on to higher levels shortly thereafter.² This can make continuity of care difficult, and communication and turnover between medical units crucial. On two occasions this entailed Corpsmen substituting the standard chest seal with make-shift duct tape and applying it on as tightly as possible; however, this additional technique failed.

PRODUCT AND APPLICATION

There are two aspects of the chest seal that are problematic. First, poor adhesion on a wet, bloody body surface is a concern. Many times the injured are still actively bleeding from the chest injury. They may also have significant sweat, which adds to this. The standard chest seal has a thin adhesive, and when it becomes wet, it does not adhere well. This then makes additional work for the caretaker attempting to maintain the seal and use up additional equipment. Second, the relatively small surface area of the Asherman[®] makes multiple penetrating injuries difficult to close. The nature of multiple projectiles entering the thorax, causing multiple wounds, makes having a larger seal advantageous. Applying fewer dressings to cover more of the wound makes more efficient use of the gear available. A larger surface can also engage with adhesiveness by providing more area for contact between the intact surrounding skin and the chest seal.

Several Corpsmen in other operational units mentioned the use of hydrogel, an adhesive their units had originally used to apply explosives to doors and windows during clearing operations (i.e. part of the Breecher's tool kit).³ Hydrogels are three dimensional polymers that contain water. When coming in contact with water, it swells but maintains its chemical and adhesive properties and does not dissolve. The compound has a wide variety of uses, including drug delivery, wound care, biomedical hardware, and electrical applications during surgical procedures. A comparison made with other skin adhesives found it to be superior when used on skin for wound care.⁴ The form of hydrogel used came as a two sided adhesive, available in a blue tint, which allows good dependable adhesion to most surfaces encountered, including those dusty, wet, or asymmetric. Hydrogel appears to adhere better in heat, which seemed logical as the same material is used to apply EKGs leads to the skin, wound healing material, and electrical pacer pads for defibrillators. We decided to improvise and apply the Asherman chest seal[®] to the hydrogel film as shown (see Figures 2 to 7). After ordering an adequate




Figure 2




Figure 3

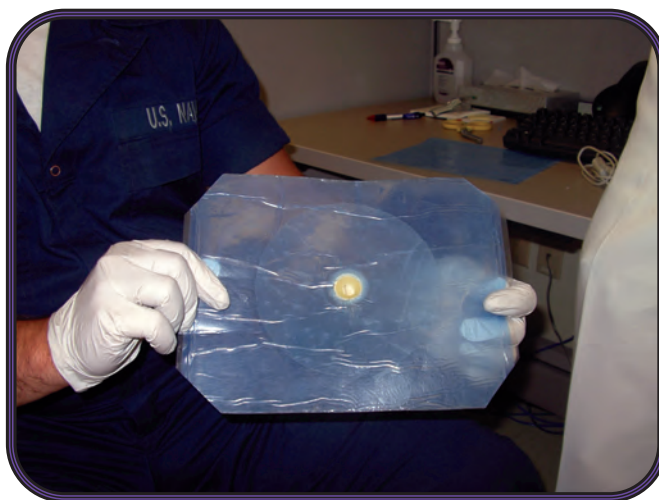


Figure 4




Figure 5

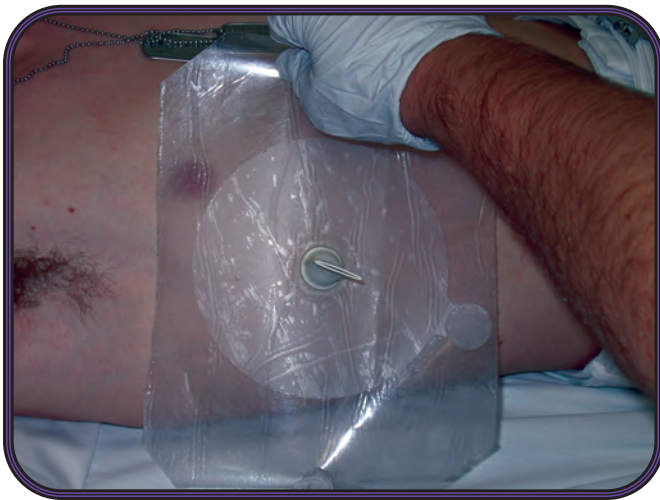


Figure 6

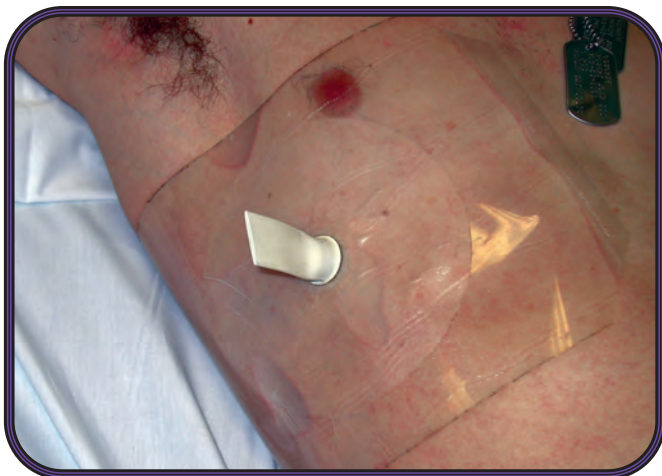


Figure 7

supply for the BAS, we made enough improvised chest seals for the staff. An appropriately-sized hole (two centimeters in diameter) was cut out of the hydrogel to allow the one way rubber valve on the chest seal to function. The chest seal was then applied to the hydrogel. The area of the adhesive seal was increased from 5.5 inches in diameter to approximately 9.5 inches with the addition of the hydrogel as shown (Figure 3) to increase efficacy.

The Corpsmen made as many as they thought necessary, and carried them along with a few of the regular chest seals, in case there were unforeseen problems with the new seals. One Corpsman treated a penetrating shrapnel wound with the improved device, and it maintained its seal despite blood and clothing obstacles. The patient was subsequently transported to a Forward Resuscitative Surgical System (FRSS) – a small, mobile trauma surgical unit designed to support U.S. Marine Corps combat operations. These task-oriented surgical units have provided effective care to combat casualties.⁵ After evaluation and monitoring at the FRSS, the patient was returned to his unit with instructions to follow up and receive wound care at the BAS (see Figures 8a & b).

DISCUSSION

The Asherman chest seal[®] lined with hydrogel showed improvement in the applicability and usefulness of the device in a real time event. It is not foolproof however, as that with any acute penetrating thoracic trauma, there tends to be significant bleeding from the wound. This makes placement and successful sealing very difficult, regardless of what system you use, and may still require additional padding with tape. It is also not known whether removing the hydrogel is also more problematic, especially for the surgeon wishing to inspect or debride the wound depending on the scenario. Based on reports of its use on burns and wound healing, one might infer that it would not be a significant complicating factor. In fact, the combination might actually be providing better care by protecting the wound from dehydration and exogenous contamination. There may also be a point of view in the trauma community who feel that the chest seals issued currently shouldn't bother to have the one-way-rubber valve because of the valve frequently becoming clotted with blood. It may provide a false sense of security that a tension pneumothorax will not develop, and invite cavalier monitoring by the care-taker. This point would argue that placing the hydrogel seal by itself would be sufficient and comparable to the efficacy of the Asherman chest seal[®]. I never received a report that there was significant blood or air coming from the one-way valve by anyone who had used the improvised chest seal. Another important point to mention is the continued

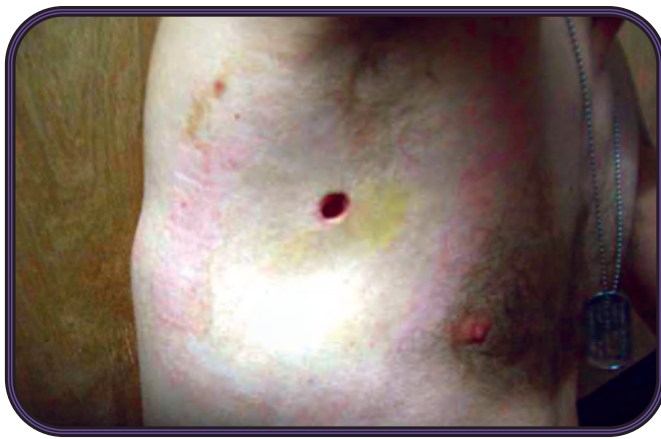

Figure 8a Entrance wound

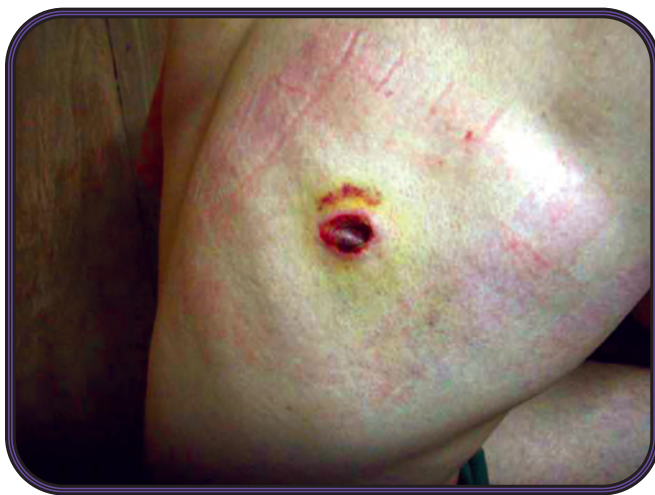

Figure 8b
Exit wound

need to monitor the patient, as a tension pneumothorax can still develop secondary to parenchymal lung injury, requiring needle decompression. The chest seal with the one-way valve does not substitute for needle decompression, but there have been published case reports of the Asherman® helping to stabilize and prevent dislodgement of needle thoracocentesis outside of a hospital setting.⁶ This might prove helpful in a combat environment where stable and deliberate patient movement may not be possible.

CONCLUSIONS

Given the nature of the combat environment of certain provinces in OIF, the high temperatures, and current logistics of medical evacuation, any improvement of the equipment should be encouraged. As long as medical inventories include the Asherman chest seal®, augmenting them with the hydrogel adhesive is beneficial, and could represent a future alternative.

The views expressed in this article are those of the author and do not necessarily reflect the official policy or

position of the Department of the Navy, Department of Defense, nor the U.S. Government.



LT Nowrouzzadeh received his undergraduate degree for the University of Connecticut. He then went on to Temple University School of Medicine, in Philadelphia, earning his medical degree. After receiving his officer commission, he completed his internship in internal medicine at National Naval Medical Center (NNMC), before joining the Marines in 2004. He returned back to NNMC, where he is currently a resident in internal medicine.

LT Nowrouzzadeh served as a battalion medical officer with the 2nd Marine Expeditionary Force out of Camp Lejeune, NC, from July 2004 to Jul of 2006. He deployed with the 2nd Marine Division to Iraq in support of Operation Iraqi Freedom (OIFIII) from 2005 to 2006. He served as the battalion surgeon for Headquarters Battalion, 2MAR-DIV in Ramadi, where he was the officer-in-charge of the battalion aid station. During his tour, he also served as the regimental surgeon for Regimental Combat Team-2, where he was involved in major combat operations including Operation Iron Fist and Operation Steel Curtain.

REFERENCES

1. Hall, Jesse B., Schmidt, Gregory A., Lawrence D.H. (2007). *Wood Principles of Critical Care, 3rd Edition*, Chapter 95. Torso Trauma, McGraw-Hill Company.
2. Gawande A. (2004). Casualties of war – military care for the wounded from Iraq and Afghanistan. *N Engl J Med*. Dec 9; 351(24):2471-5.
3. Hydrogel Ordering and Product Detail Information accessed at <http://www.amronintl.com/diving/products.cfm?id=2105>
4. Skelhorne G., Munro H. (2002). Hydrogel adhesives for wound-care applications. *Med Device Technol*. Nov;13(9):19-23.
5. Chambers L.W., Green D.J., Gillingham B.L., Sample K., Rhee P., Brown C., Brethauer S., Nelson T., Narine N., Baker B., Bohman H.R. (2006). The experience of the U.S. Marine Corps' Surgical Shock Trauma Platoon with 417 operative combat casualties during a 12 month period of operation Iraqi Freedom. *J Trauma*. Jun;60(6):1155-61.
6. Allison, K., Porter, K.M., Mason, A.M. (2002). Use of the Asherman chest seal® as a stabilization device for needle thoracotomy *Emerg Med J*;19:590–591.

Reviewer's Comment

I read the article “A Novel Application of Hydrogel to Improve the Asherman Chest Seal® in a Deployed Environment” and wanted to inform you we have been working with Teleflex Med, the producers of the Asherman, for about two years on this issue. We have finalized the improved version of the Asherman and the adhesive has been dramatically improved. We also addressed the size issue and after an initial fielding of the same sized 5” disk, there will be a 7” version fielded. So far, the new adhesive is outperforming anything that is now commercially available. This dressing will be assigned an NSN for military use and we have asked that they put it in an easy opening, mil-colored package. We are in the final phases of getting this to the guys; it should be within months. Realize that hydrogel in higher temps and humidity does not perform all that well. It tends to revert back to a very watery substance. I just used the older Asherman on my last trip and they failed terribly, no surprise. Also used the new Hyfin Chest Seal and these performed extremely well in very difficult conditions. I can send you a quick AAR on this case but don't want to bore you. Our medics were initially carrying hydrogel as a replacement, but are now moving to Hyfins.

JSOM Disclaimer Statement: The JSOM presents both medical and nonmedical professional information to expand the knowledge of SOF military medical issues and promote collaborative partnerships among services, components, corps, and specialties. It conveys medical service support information and provides a peer-reviewed, quality print medium to encourage dialogue concerning SOF medical initiatives. The views contained herein are those of the authors and do not necessarily reflect the Department of Defense. The United States Special Operations Command and the Journal of Special Operations Medicine do not hold themselves responsible for statements or products discussed in the articles. Unless so stated, material in the JSOM does not reflect the endorsement, official attitude, or position of the USSOCOM-SG or of the Editorial Board.